Ultrasound and IBD

Kerri Novak, MD, FRCPC, University of Calgary
Cathy Lu, MD, FRCPC, University of Alberta
February 27, 2016

Inflammatory Bowel Disease Group
University of Calgary

UNIVERSITY OF CALGARY
CUMMING SCHOOL OF MEDICINE

Canadian Association of Gastroenterology
L'Association Canadienne de Gastroentérologie

UNIVERSITY OF ALBERTA
QUAECUMQUE VERA

Accreditation

This event is an accredited (Section 1) group learning activity as defined by the Maintenance of Certification program of the Royal College of Physicians and Surgeons of Canada (RCPSC). The program was produced under the RCPSC guidelines for the development of co-developed educational activities between the Canadian Association of Gastroenterology (CAG) and Merck Canada Inc.

Dr. Cathy Lu

Financial Interest Disclosure

(over the past 24 months)

No relevant financial relationships with any commercial interests

Name: Dr. Kerri Novak

Financial Disclosures

(over past 24 months)

	Speaker	Advisory	Research	Consultant
Abbvie	√	√	√	
Janssen	√	√	√	
Ferring		√		
Pendopharm	√	√		

Learning Objectives

At the end of this session, participants will be able to:

1. Understand the merits of available imaging modalities (US, CT, MR) for both diagnosis and monitoring of patients with or suspected of having IBD
2. Recognize four key sonographic components of active IBD, review a simple score for disease activity (Simple Ultrasonographic Score/SUS) and identify complications of IBD on bowel ultrasound
3. Understand how ultrasound may be used in clinical decision-making
4. Recognize how ultrasound can be used in the future as a clinical tool to differentiate between IBS and IBD in patients referred for symptoms such as diarrhea

CanMEDS Roles Covered:

X	**Medical Expert** (as *Medical Experts*, physicians integrate all of the CanMEDS Roles, applying medical knowledge, clinical skills, and professional values in their provision of high-quality and safe patient-centered care. *Medical Expert* is the central physician Role in the CanMEDS Framework and defines the physician's clinical scope of practice.)
	Communicator (as Communicators, physicians form relationships with patients and their families that facilitate the gathering and sharing of essential information for effective health care.)
X	**Collaborator** (as *Collaborators*, physicians work effectively with other health care professionals to provide safe, high-quality, patient-centred care.)
	Leader (as *Leaders*, physicians engage with others to contribute to a vision of a high-quality health care system and take responsibility for the delivery of excellent patient care through their activities as clinicians, administrators, scholars, or teachers.)
X	**Health Advocate** (as *Health Advocates*, physicians contribute their expertise and influence as they work with communities or patient populations to improve health. They work with those they serve to determine and understand needs, speak on behalf of others when required, and support the mobilization of resources to effect change.)
	Scholar (as *Scholars*, physicians demonstrate a lifelong commitment to excellence in practice through continuous learning and by teaching others, evaluating evidence, and contributing to scholarship.)
	Professional (as *Professionals,* physicians are committed to the health and well-being of individual patients and society through ethical practice, high personal standards of behaviour, accountability to the profession and society, physician-led regulation, and maintenance of personal health.)

Objective #1 - Imaging Modalities

- Understand the merits of commonly used imaging modalities for both diagnosis and monitoring of patients with IBD through cases

Case 1 JP

- 27yo single father, on anti-TNF mono Rx.
- Developed tooth abscess, fistula to sinuses – all upper teeth extracted, antibiotics, anti-TNF held for >1 yr

Active peri-anal disease, lost 40lbs, vomiting daily

Endoscopic Evaluation 2014

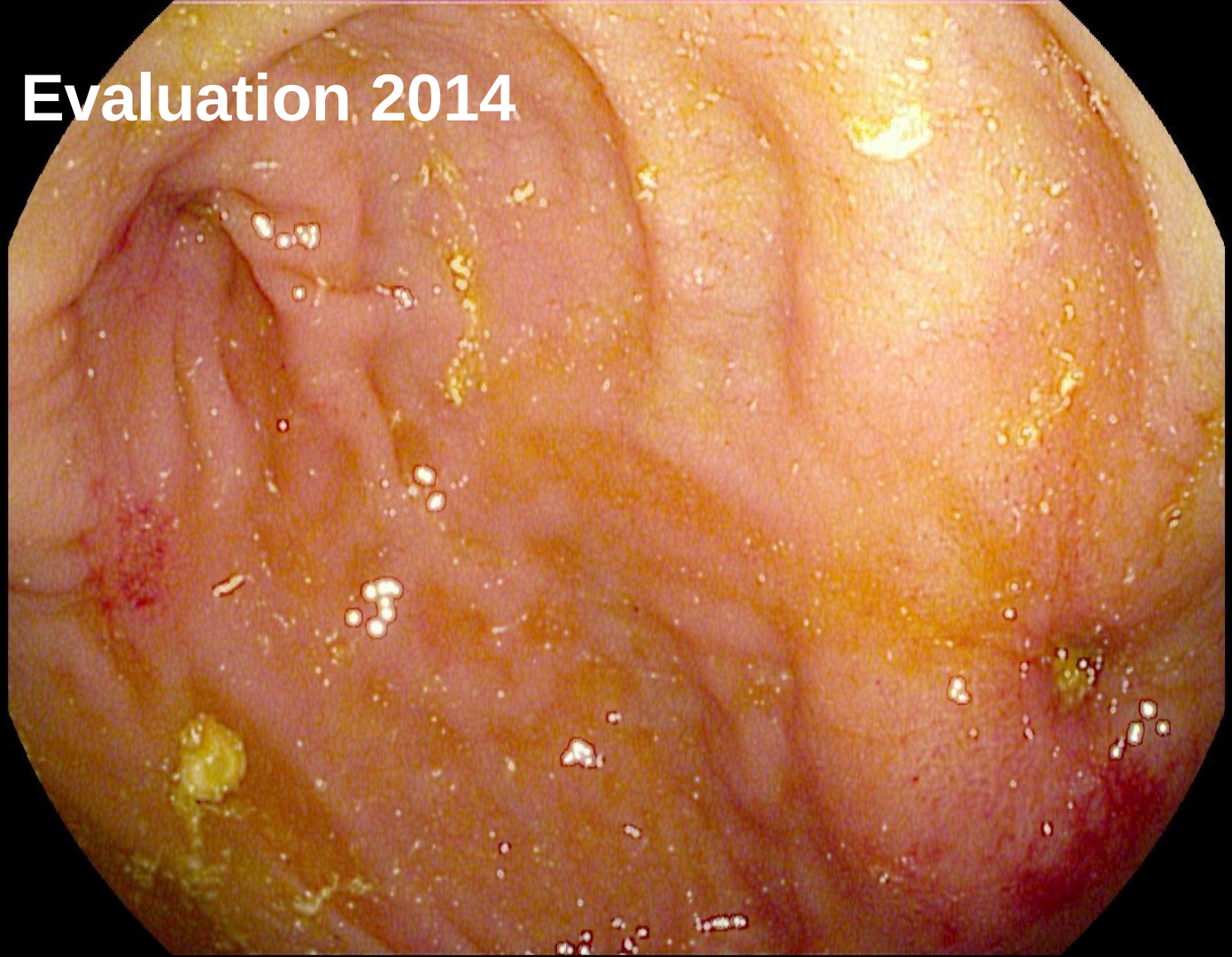

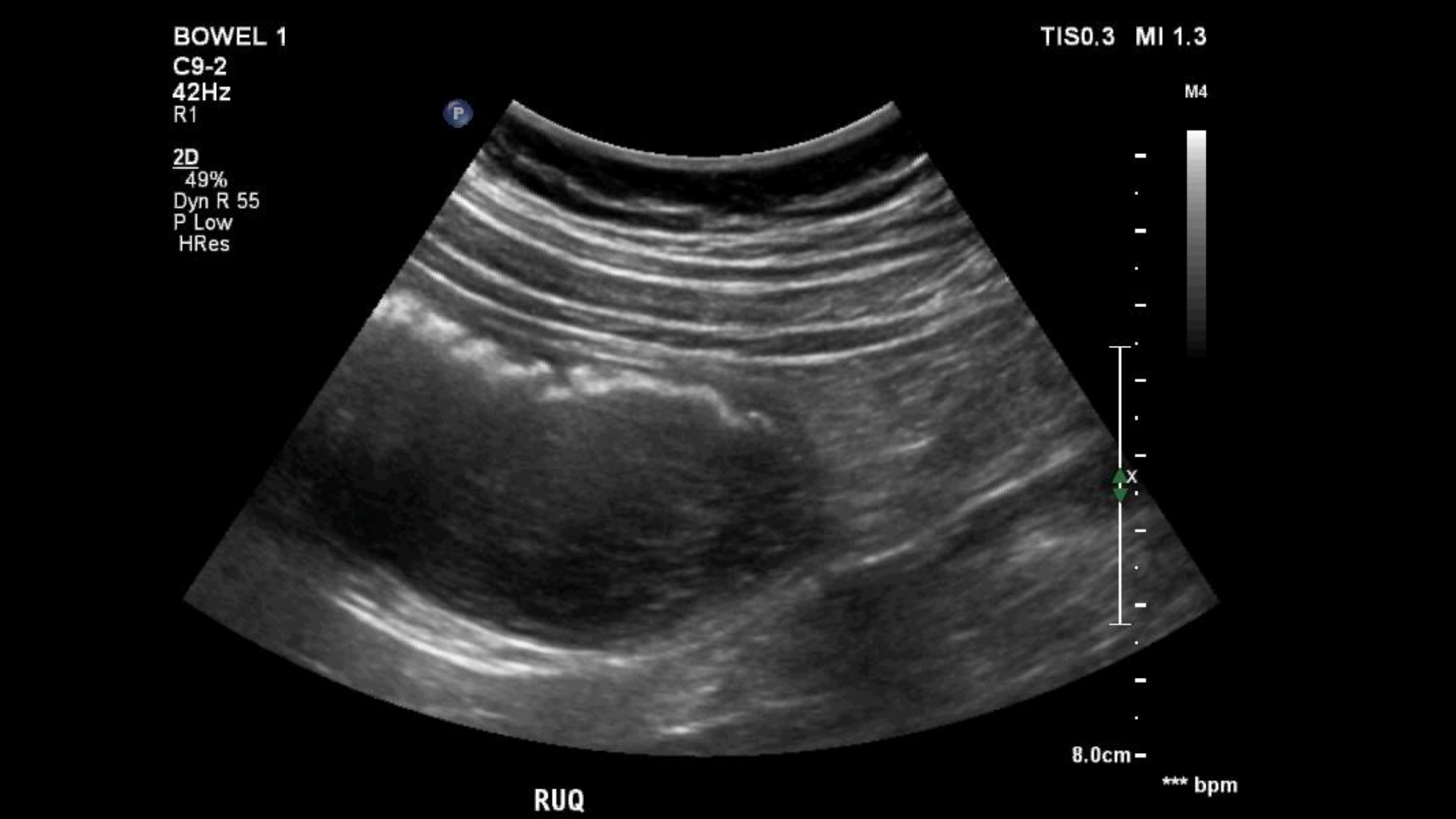
BOWEL 1
C9-2
42Hz
R1
2D
49%
Dyn R 55
P Low
HRes
TIS0.3 MI 1.3
M4
8.0cm
*** bpm
RUQ

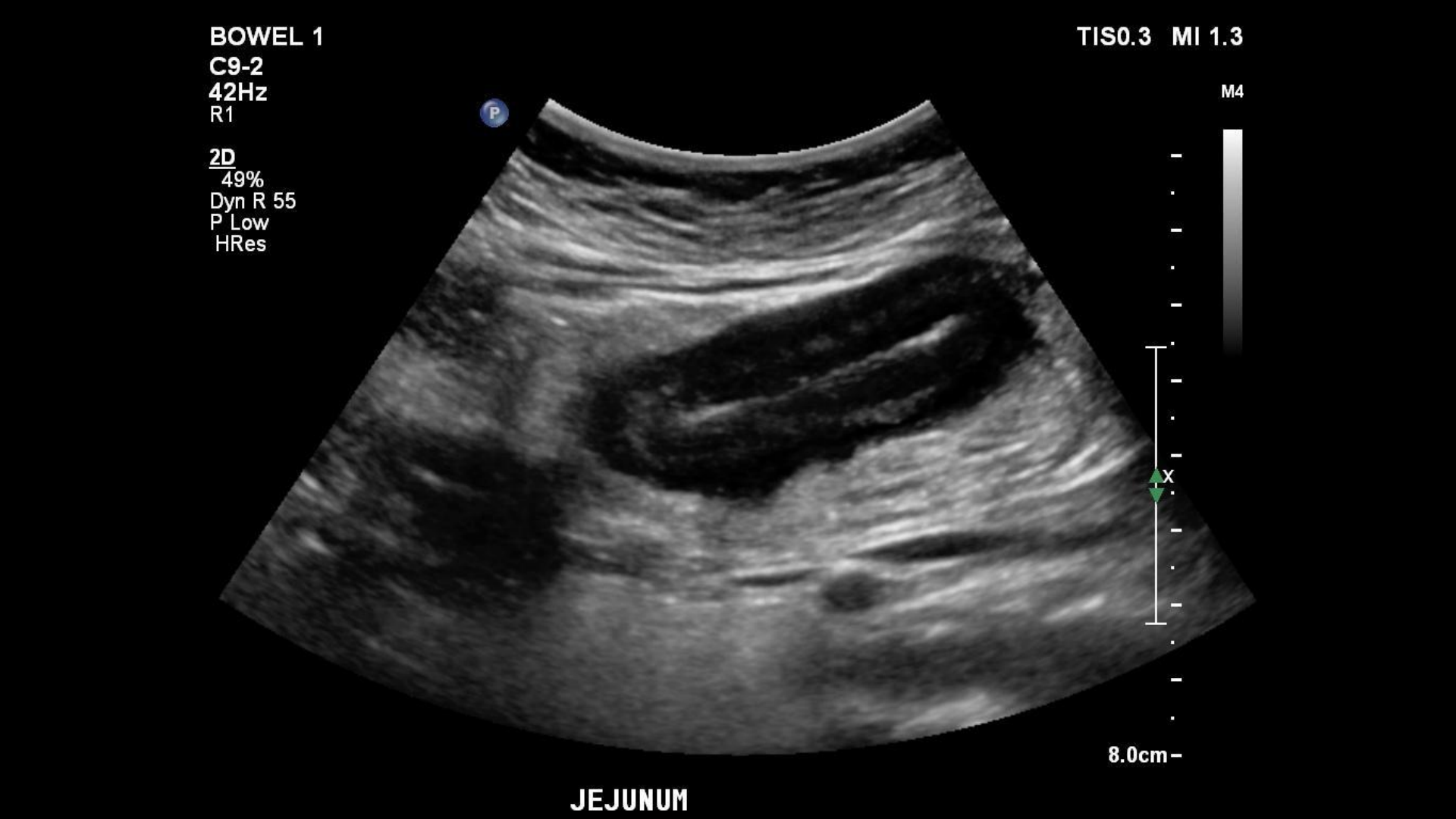
BOWEL 1
C9-2
42Hz
R1
2D
49%
Dyn R 55
P Low
HRes
TIS0.3 MI 1.3
M4
P
X
8.0cm
JEJUNUM

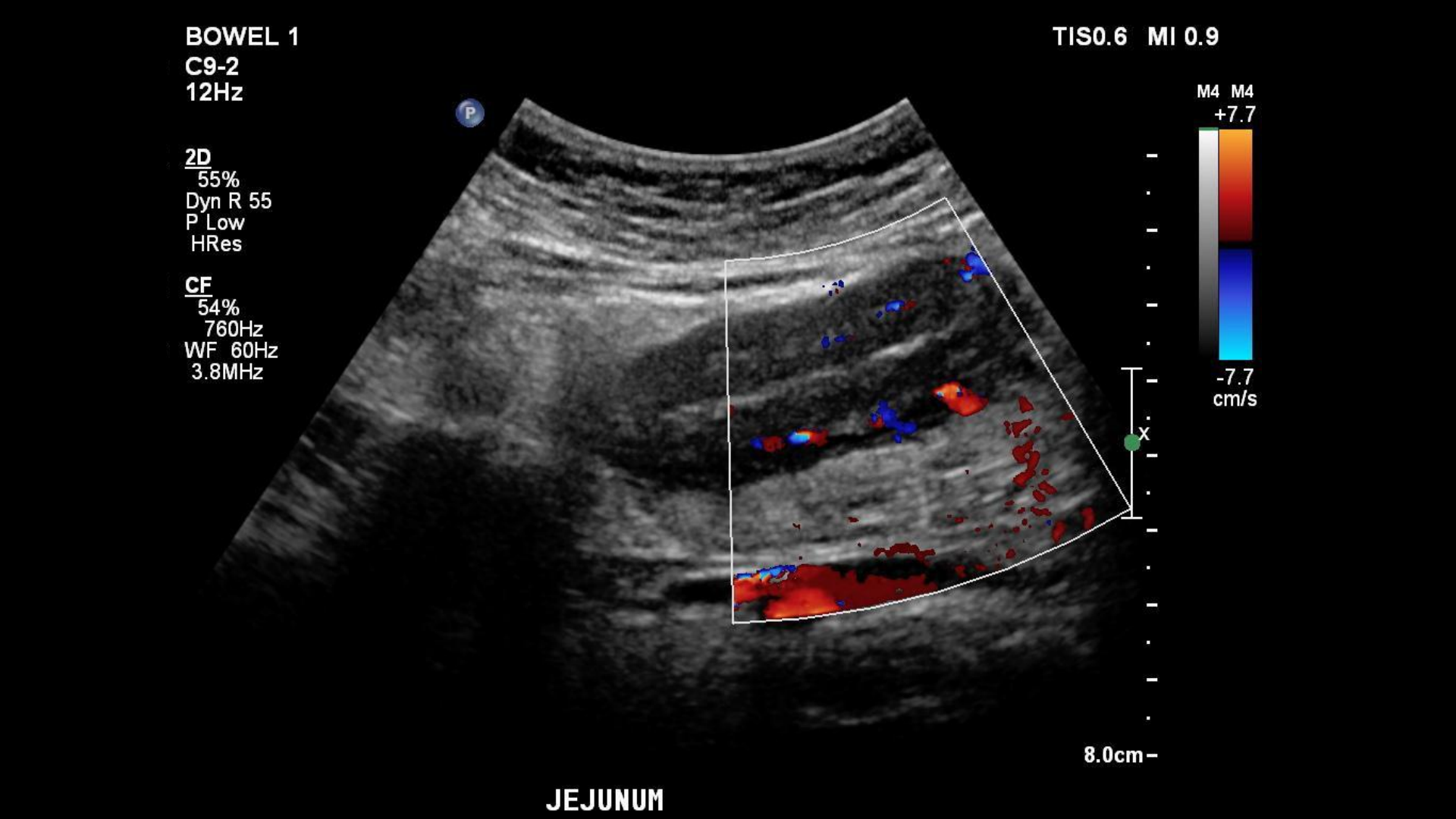
BOWEL 1
C9-2
12Hz
2D
55%
Dyn R 55
P Low
HRes
CF
54%
760Hz
WF 60Hz
3.8MHz
TIS0.6 MI 0.9
M4 M4
+7.7
-7.7
cm/s
8.0cm
JEJUNUM

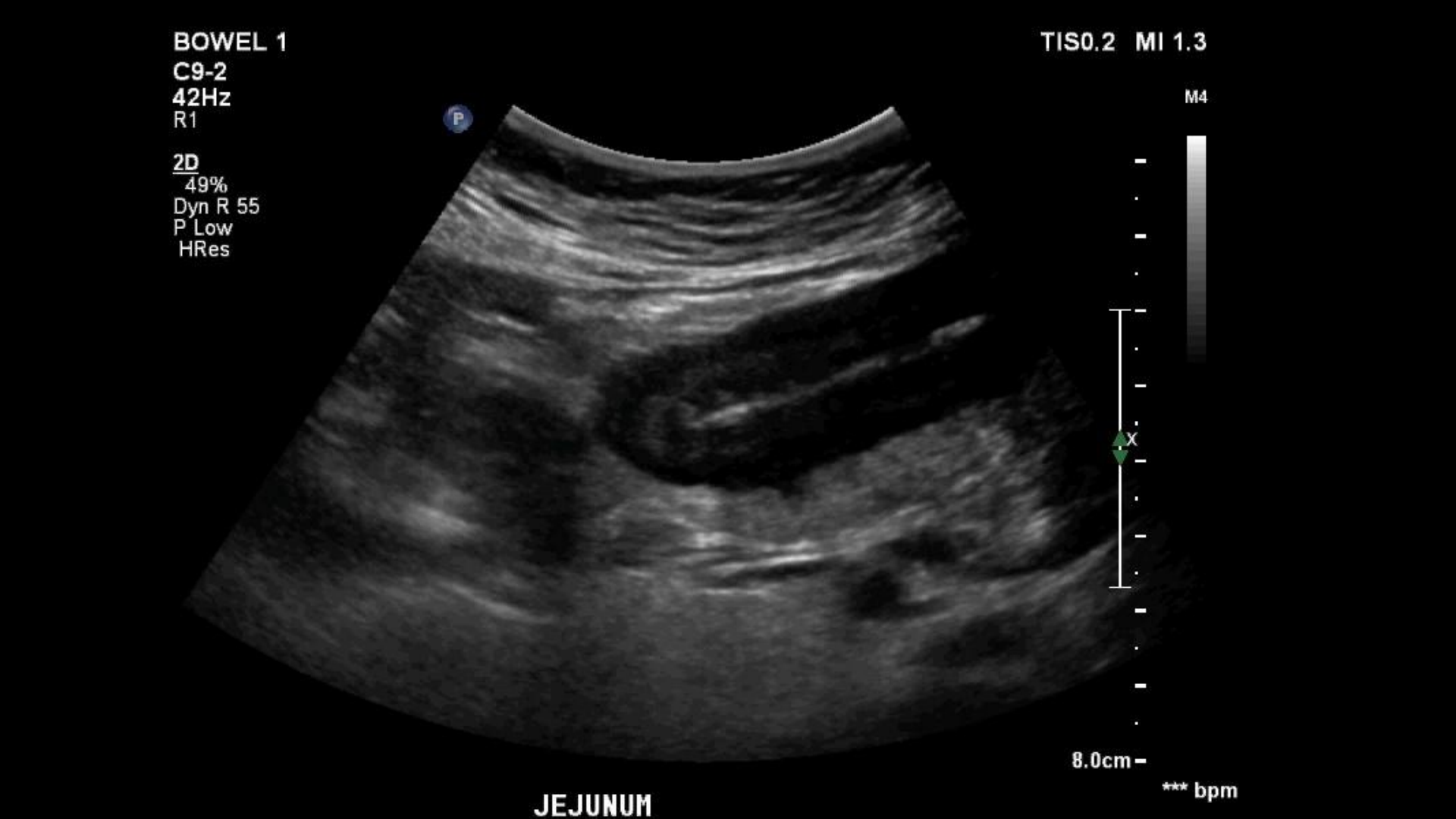
BOWEL 1
C9-2
42Hz
R1
2D
49%
Dyn R 55
P Low
HRes
TIS0.2 MI 1.3
M4
P
X
8.0cm
*** bpm
JEJUNUM

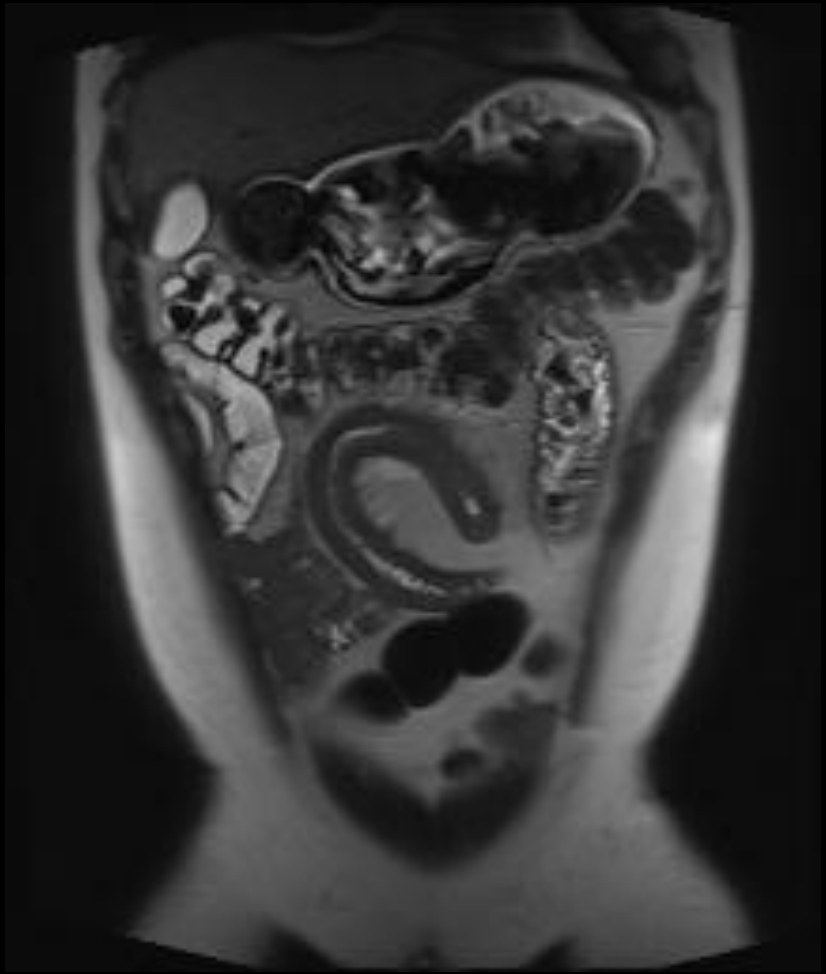

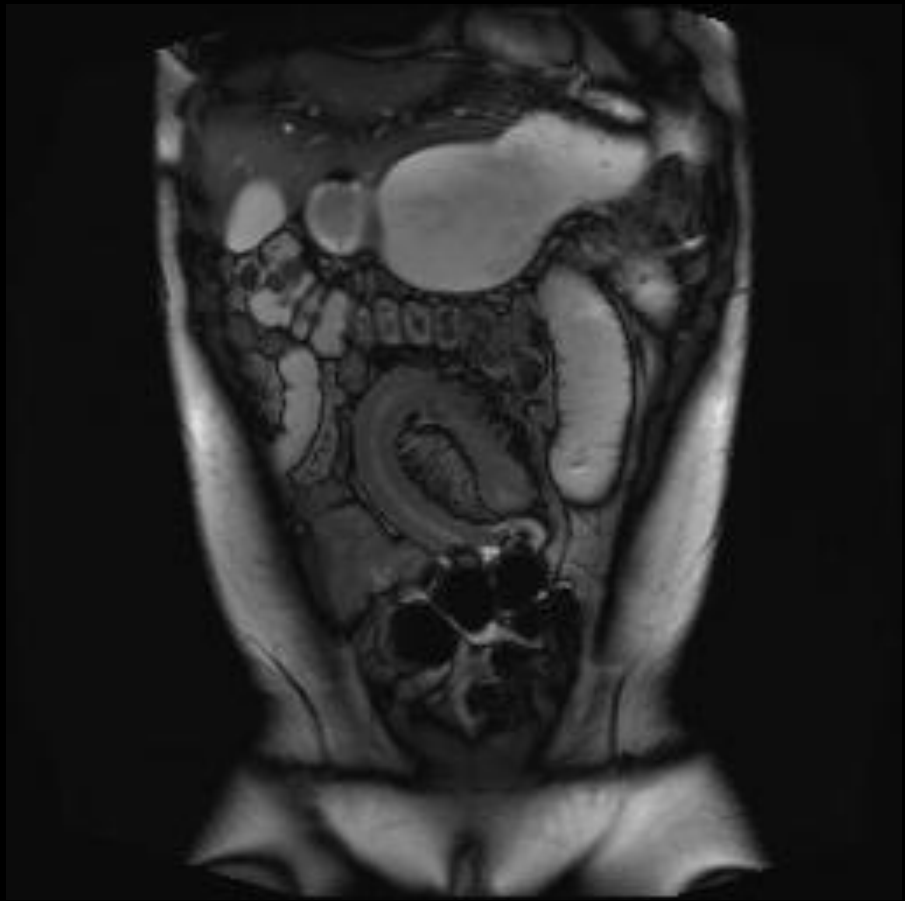

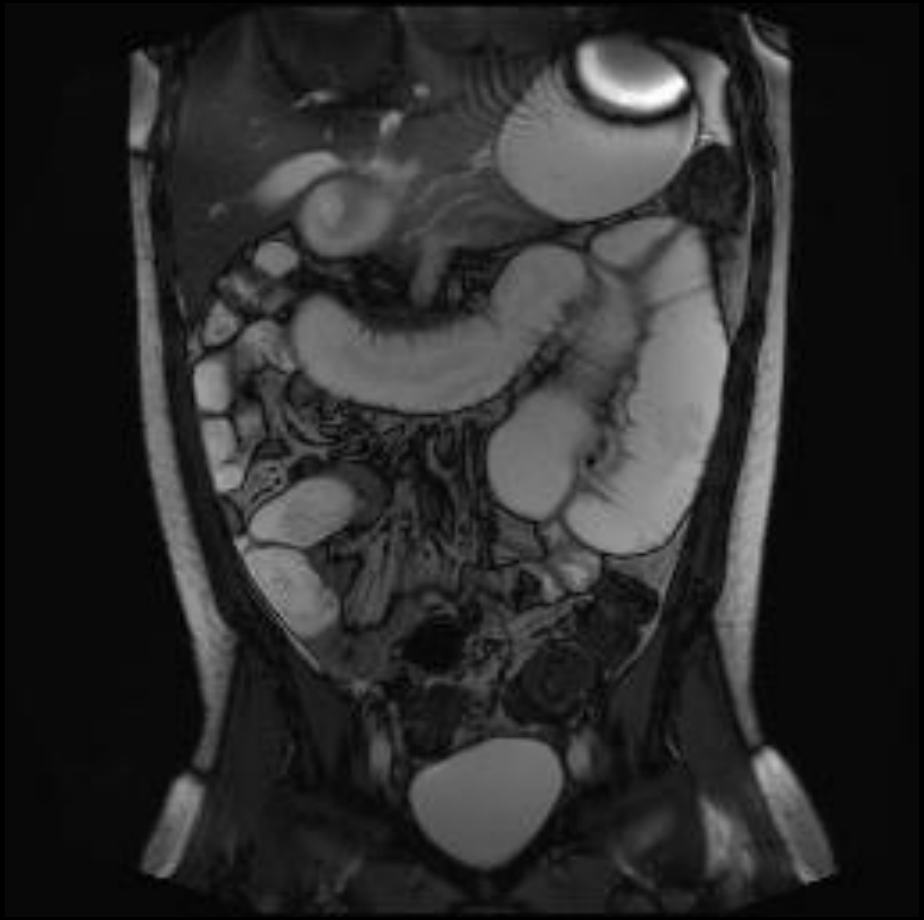

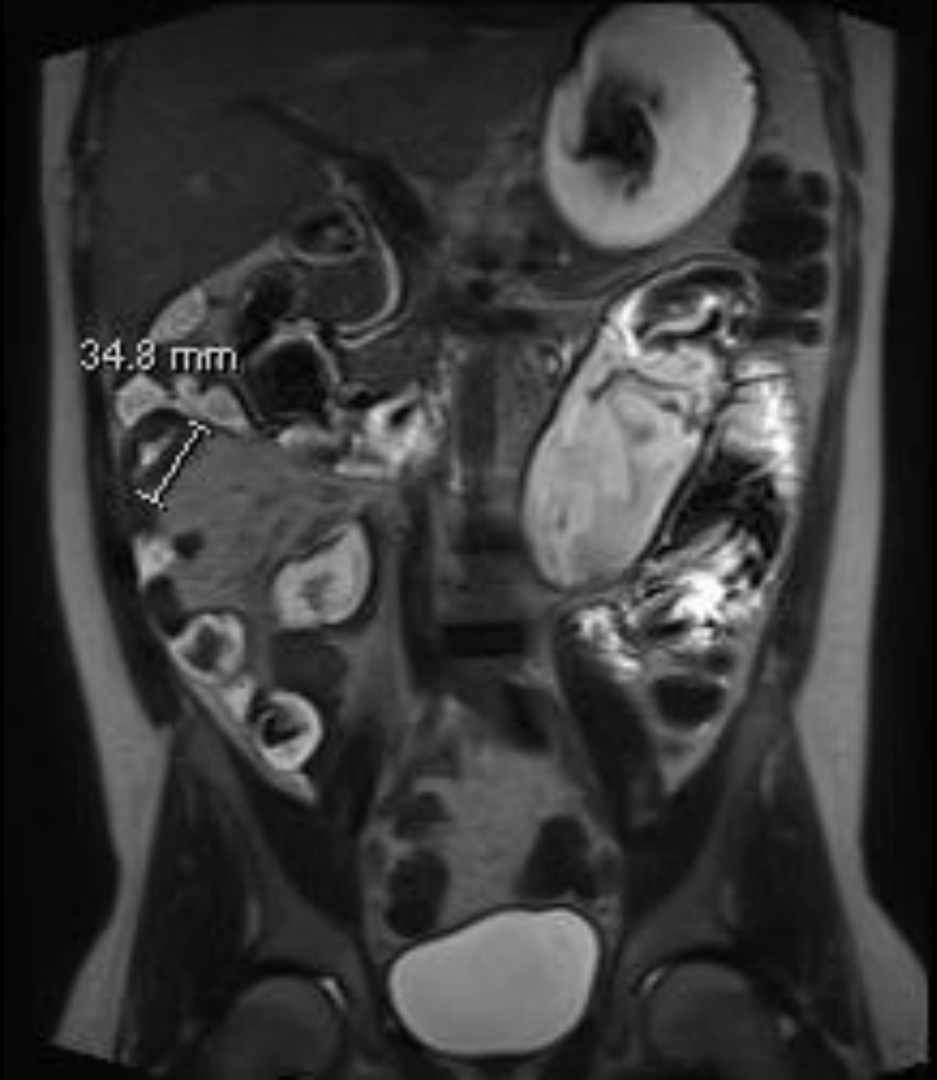
34.8 mm

Take Home 1.

Clinic based triage / decision tool

Cross-modality comparison informative

Peri-anal disease characterization best achieved w either US or MR

Case 2. AB

- 67 yo man with a 6yr history of periodic severe belly pain, vomiting (classic SBO Sx) — otherwise completely well with well-controlled HTN

- Normally controlled Sx by NPO – however recent episode slow to resolve, presented to ED & admitted under surgery.

- CT suggests “thickened TI” – referred to GI to “rule out CD”

Calcified Lymph Node

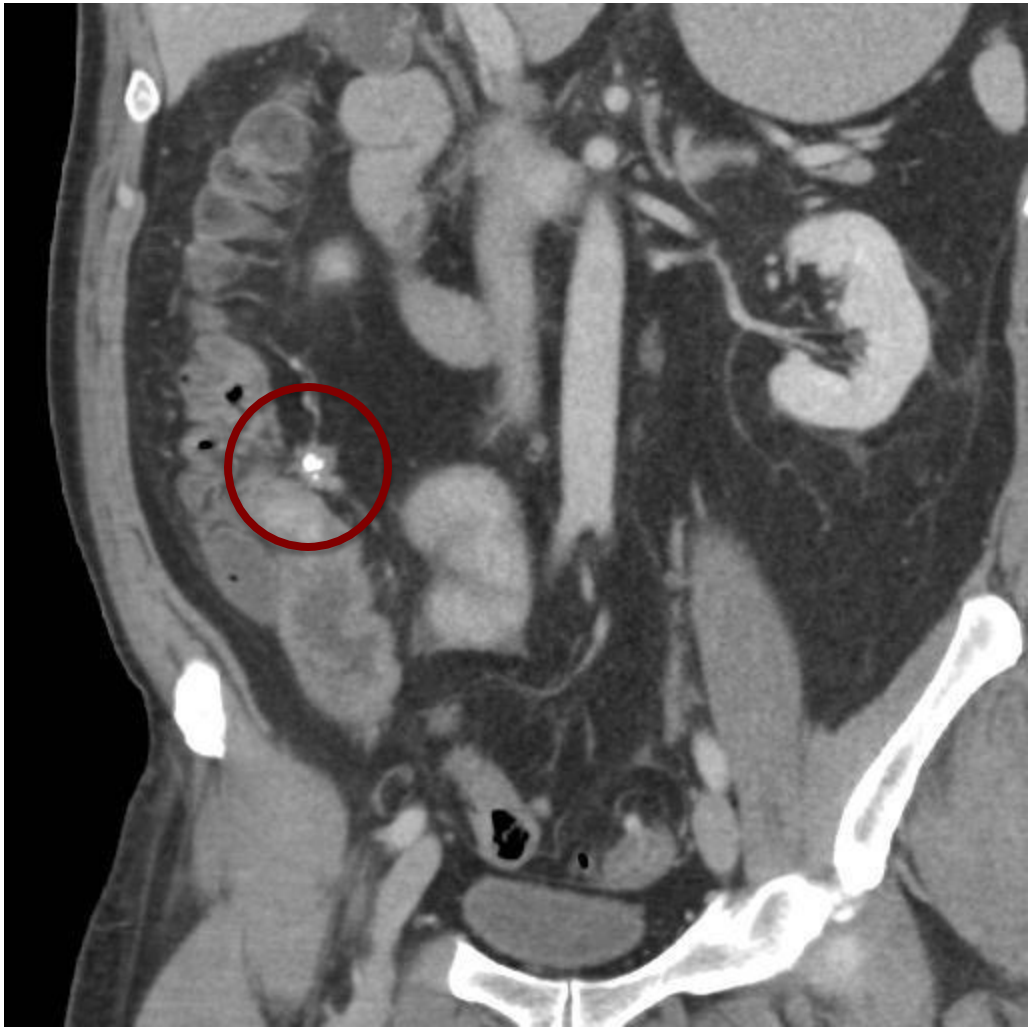

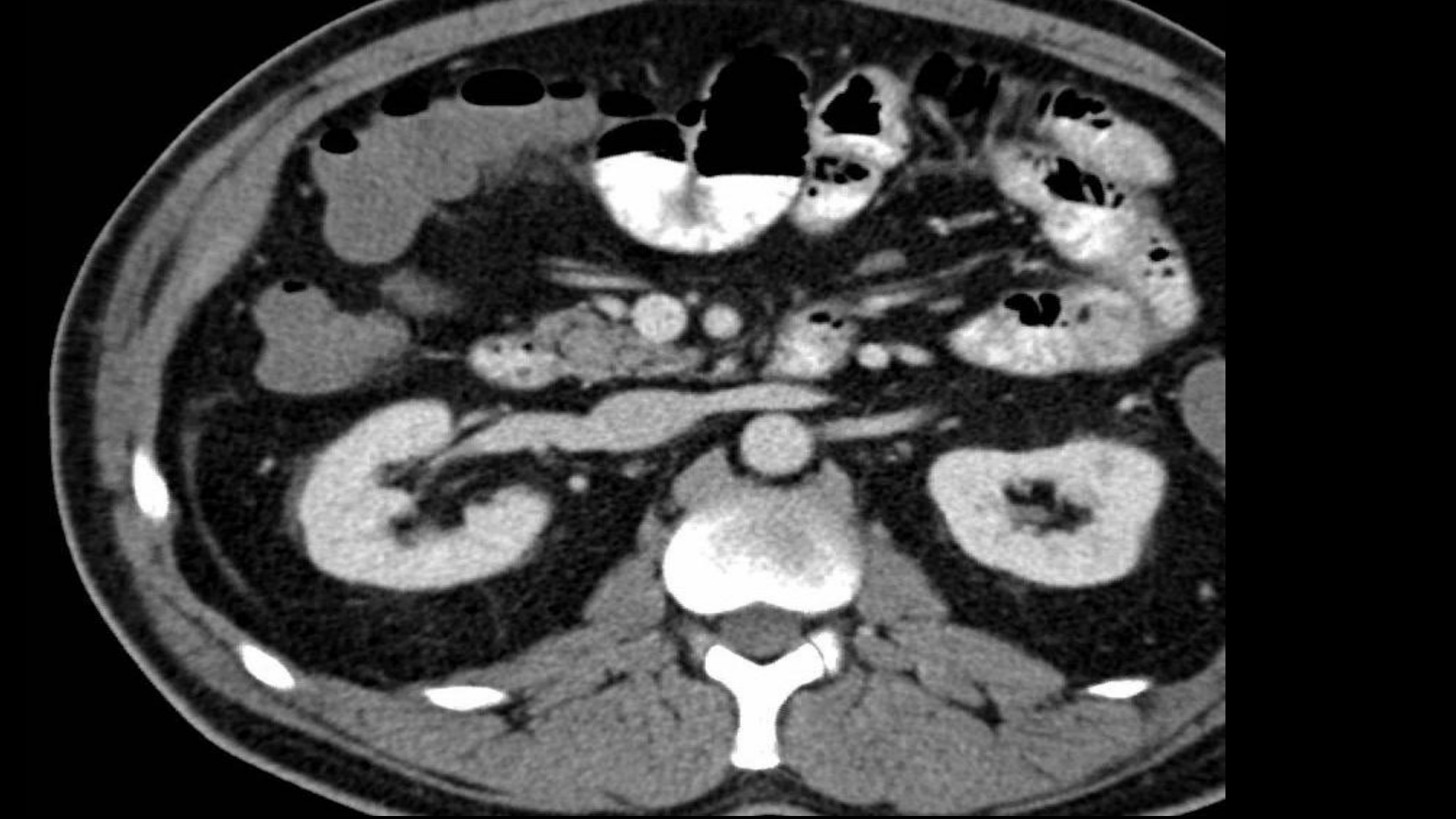

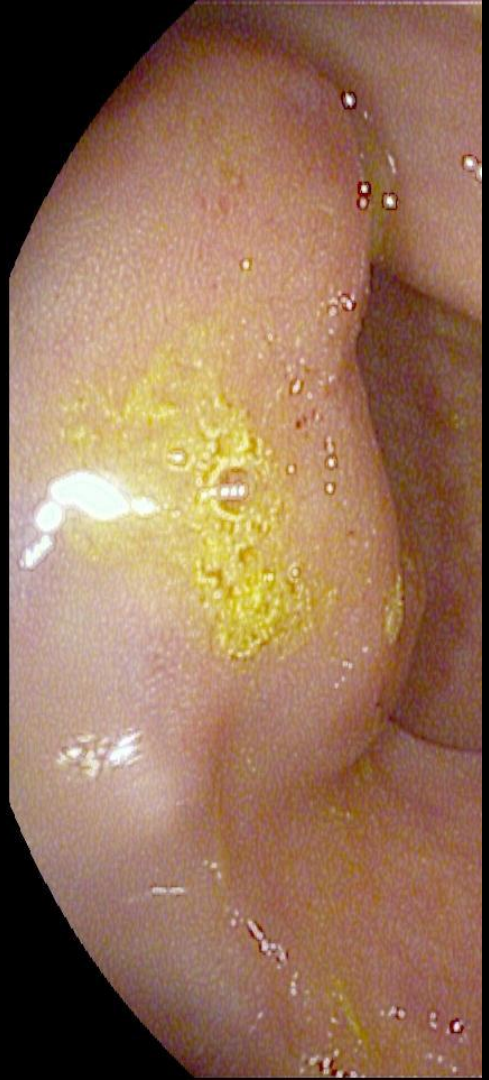

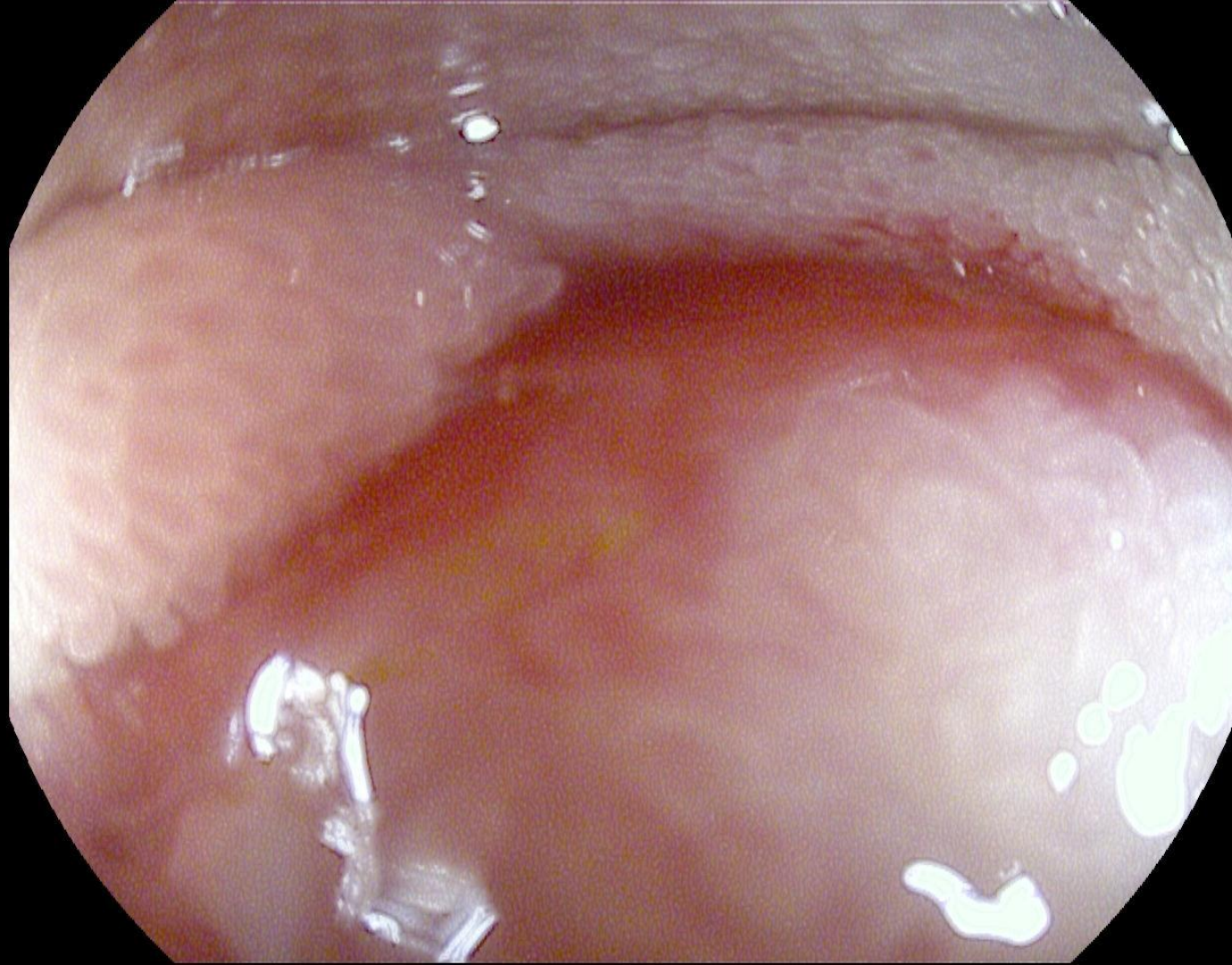



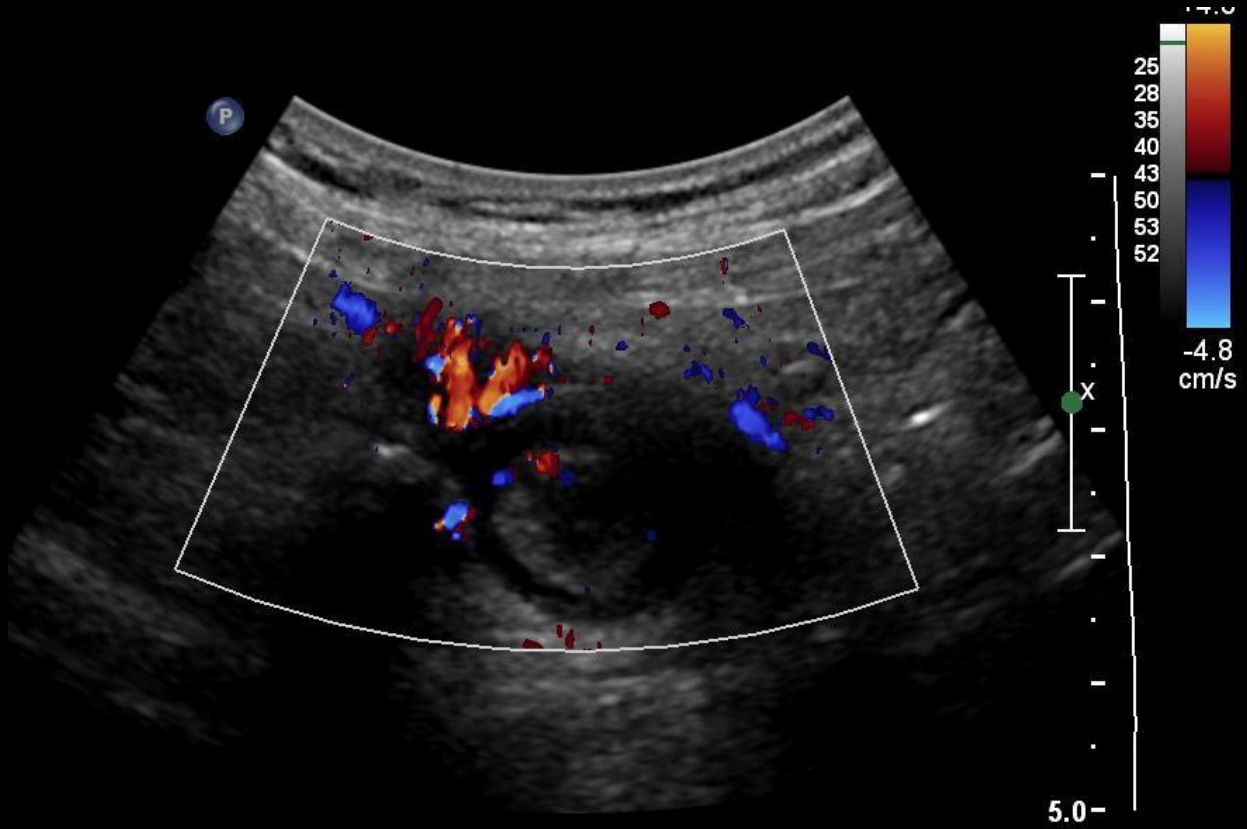

RLQ

Take Home 2

- Not all that is TI thickening on CT is CD…

- US depicts real-time gut function, MR & CT static

Case 3. PT

- 27 man from Northern AB, seen in 2012 given Dx of CD.
- Endoscopy revealed “inflammatory SC stricture” with ability to pass – remainder of the colon was normal, distal TI, mild inflammation.

- Started on ant-TNF therapy, lost to follow up.

Case 3. PT

- Presented to Urgent Care in Calgary, 20 pound weight loss, fever & chills, unwell.









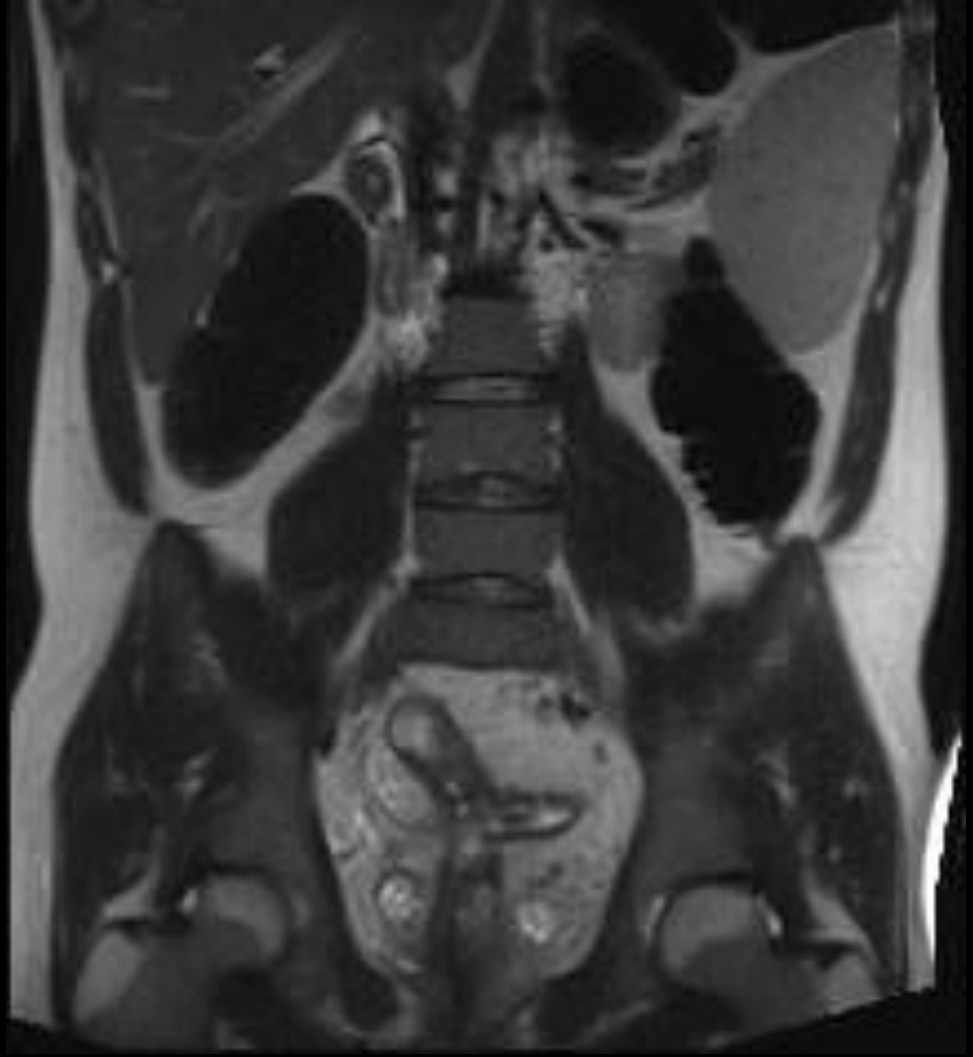

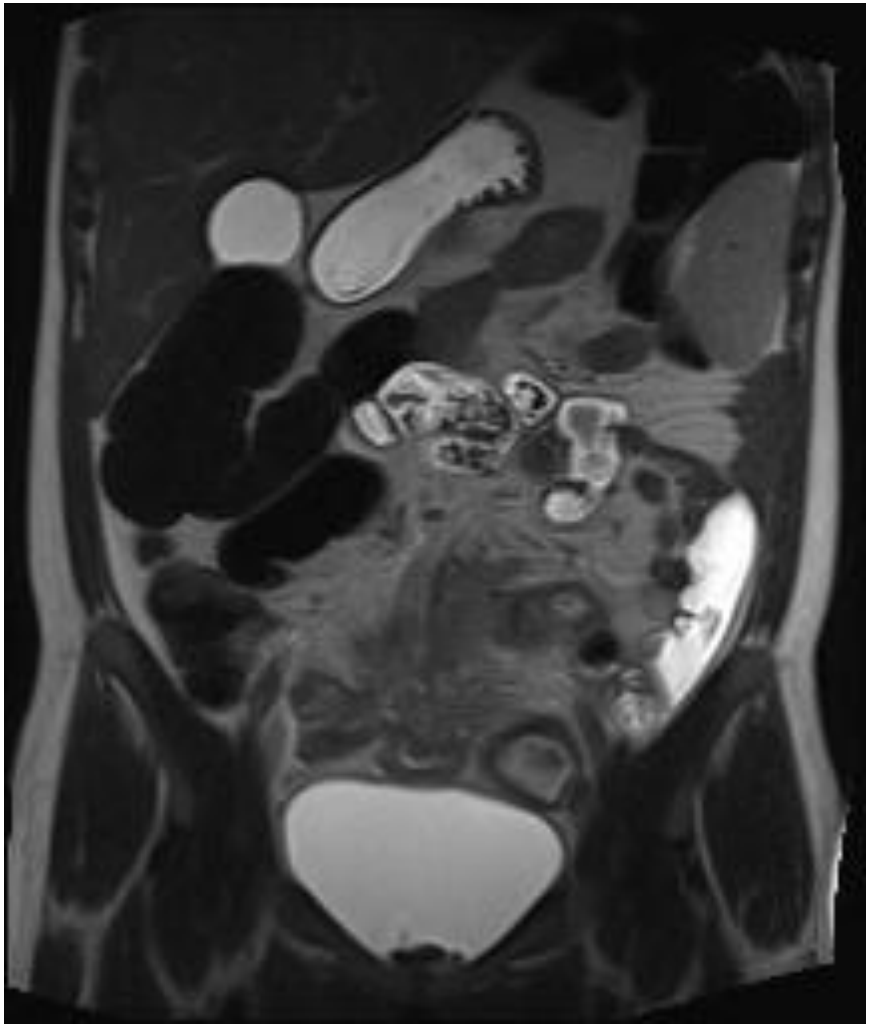

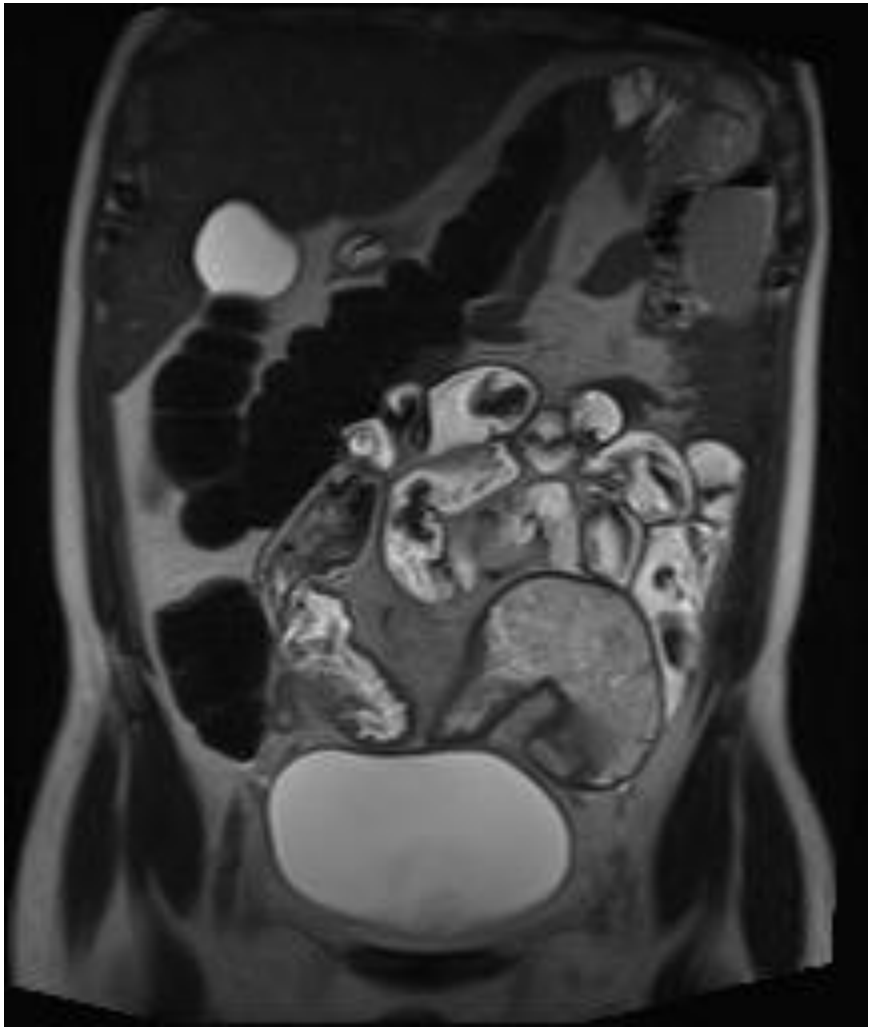

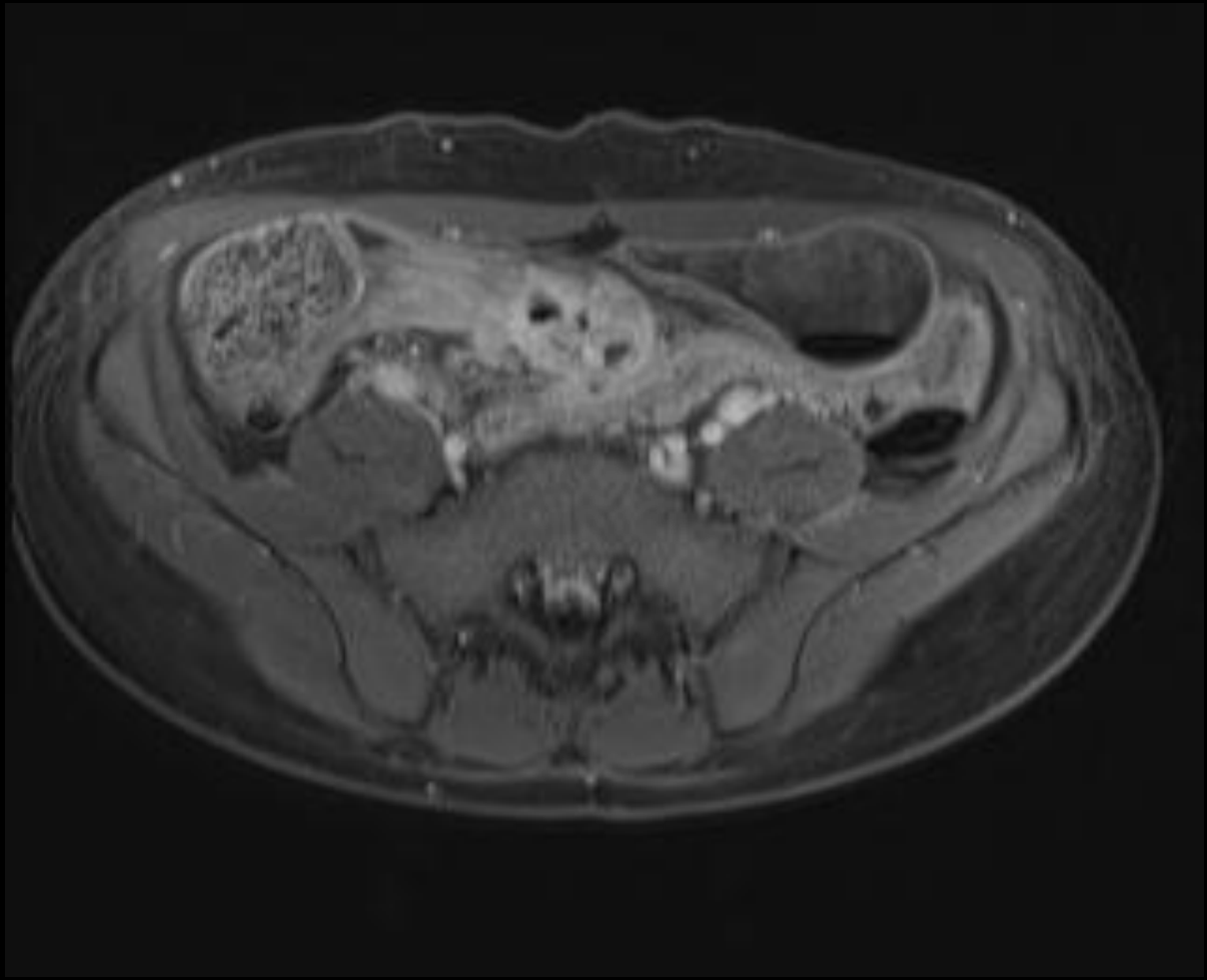

Take Home 3

Complex patient – requires multiple imaging modalities

Dedicated imaging is ESSENTIAL pre-treatment – endoscopic entry into the TI is not sufficient to exclude proximal disease

US depicts the air-containing pelvic phlegmon – seeding/ multiple abscesses depicted by CT throughout the abdomen

CT Enterography/CT Abdo

- Widely available
- High spatial and anatomic resolution
- Rapid acquisition time

Limitations

- Radiation exposure
- Detection of fibrosis? [1]

1. Adler, J., et al., Inflamm Bowel Dis, 2012. **18**(5): p. 849-56.

Low Dose CT

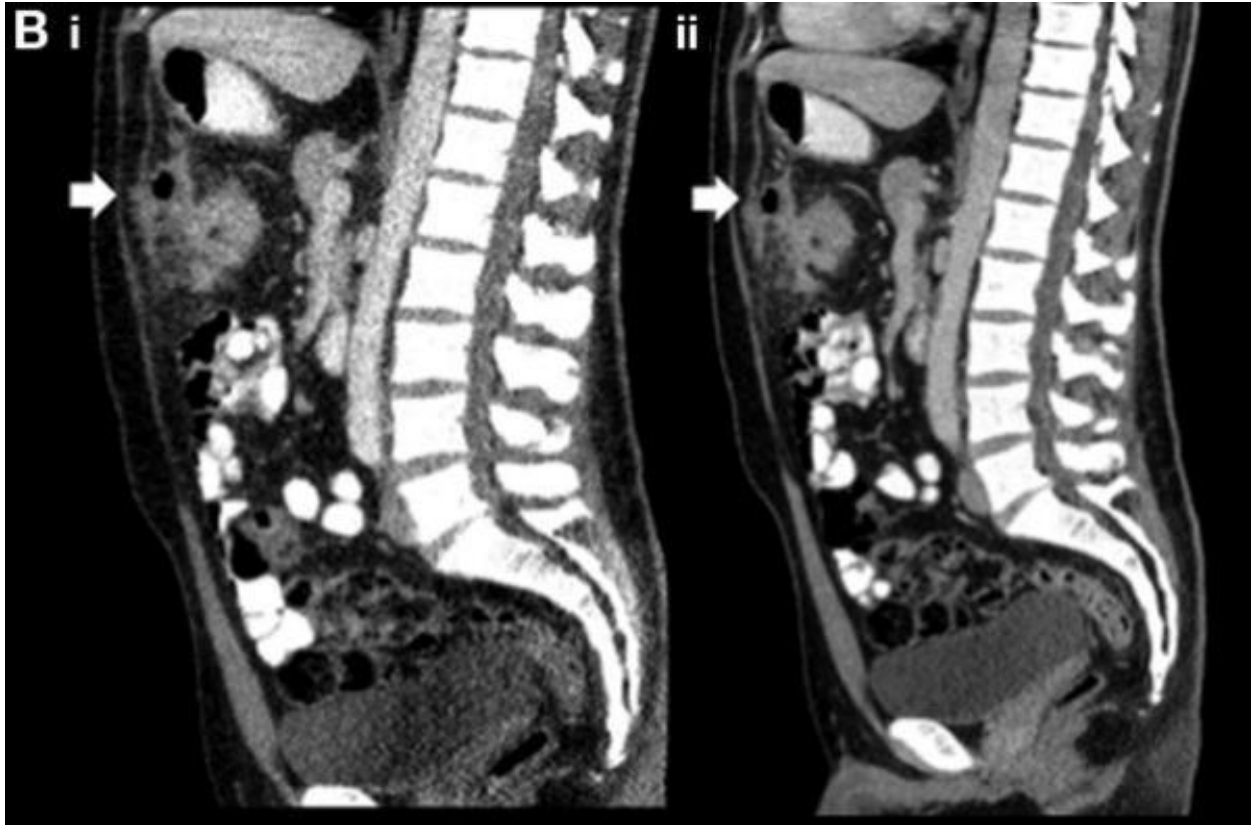

Craig et al. 2012
Clin Gastro Hep;
10(8):886

MR/ MREnterography

- Excellent soft tissue contrast
- Considered gold standard for peri-anal disease
- May assess fibrosis irrespective of the amount of concurrent inflammation[1]

Limitations

- High cost
- Significant potential for motion artifact
- Limited access in many centers – long wait times
- Expertise-dependent
- LONG acquisition time – 45 min in the magnet

1. Rimola, J., et al., Am J Gastroenterol, 2015. **110**(3): p. 432-40.

Ultrasound (US)

- US is a highly effective, safe, and tolerable imaging modality
- Dynamic real-time imaging
- US in reviews and meta-analyses is equally sensitive and specific to CT and MRI in diagnosing and monitoring CD [1-3]
- Bowel wall thickness and colour doppler are significantly correlated with severity grade at endoscopy [4].

1. Allocca, M., et al, Dig Dis, 2013. **31**(2): p. 199-201.
2. Horsthuis, K., et al., Radiology, 2008. **247**(1): p. 64-79.
3. Panes, J., et al., Aliment Pharmacol Ther, 2011. **34**(2): p. 125-45.
4. Ripolles, T., et al., Radiology, 2009. **253**(1): p. 241-8.

Ultrasound Limitations

- Specialized skill
- Operator dependent
- Labor intensive
- Inter-rater variability
- Anatomic resolution - challenging

US in Gastroenterology

- Many benefits – dedicated small bowel imaging combined with clinical & serological markers is the future of GI for monitoring IBD

- Patient engagement
- Renumeration, time, learning curve, initial investment - equipment

Objective #2

- Recognize the key sonographic components of active IBD & review a simple score for disease activity (Simple Ultrasonographic Score/SUS), identify complications of IBD on bowel ultrasound

Bowel Wall Thickness

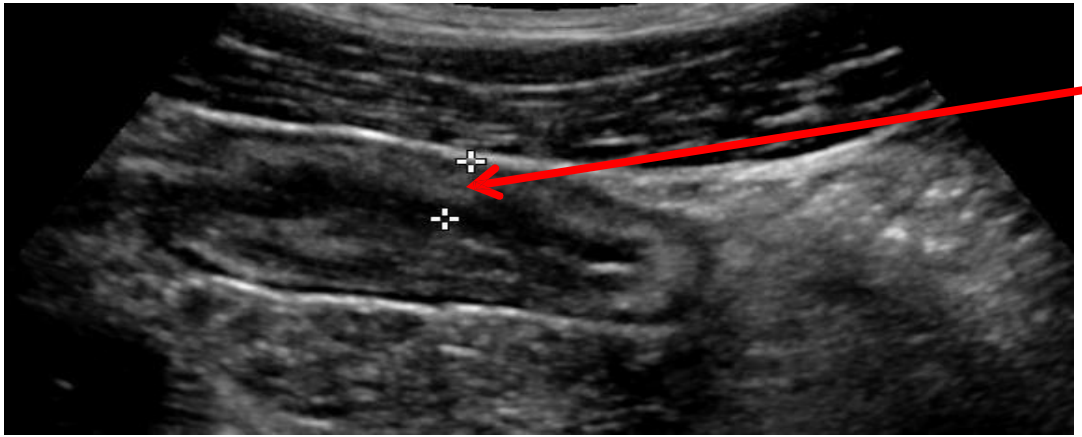

- On US, bowel wall thickness has been shown to be the best parameter for detecting active disease[1].
- A bowel wall thickness of 3mm has been shown to have a sensitivity of 88% and a specificity of 93% for detecting active CD[2]

1. Moreno N, Ripolles T, Paredes JM, et al. J Crohn's Colitis. 2014; pii: S187.
2. Fraquelli M, Colli A, Casazza G, et al. Radiology 2005; 236:95-101.

Thickened Bowel Wall

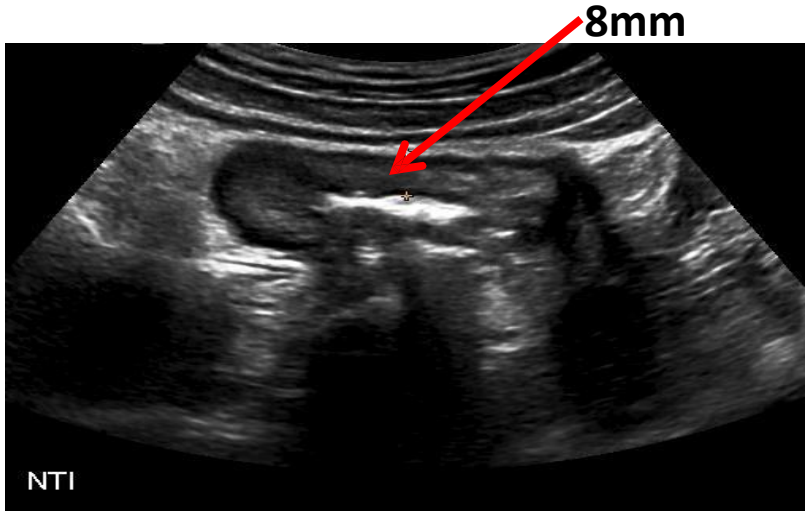

Longitudinal View

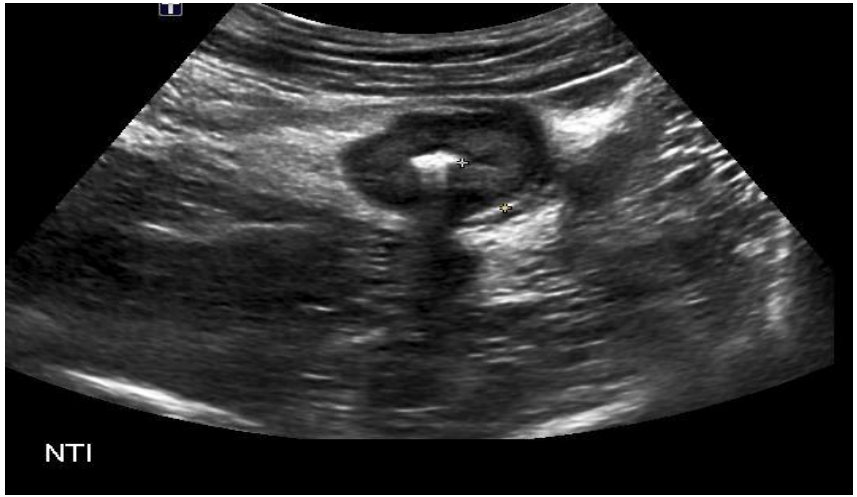

Axial View

Echogenic Mesenteric Fat

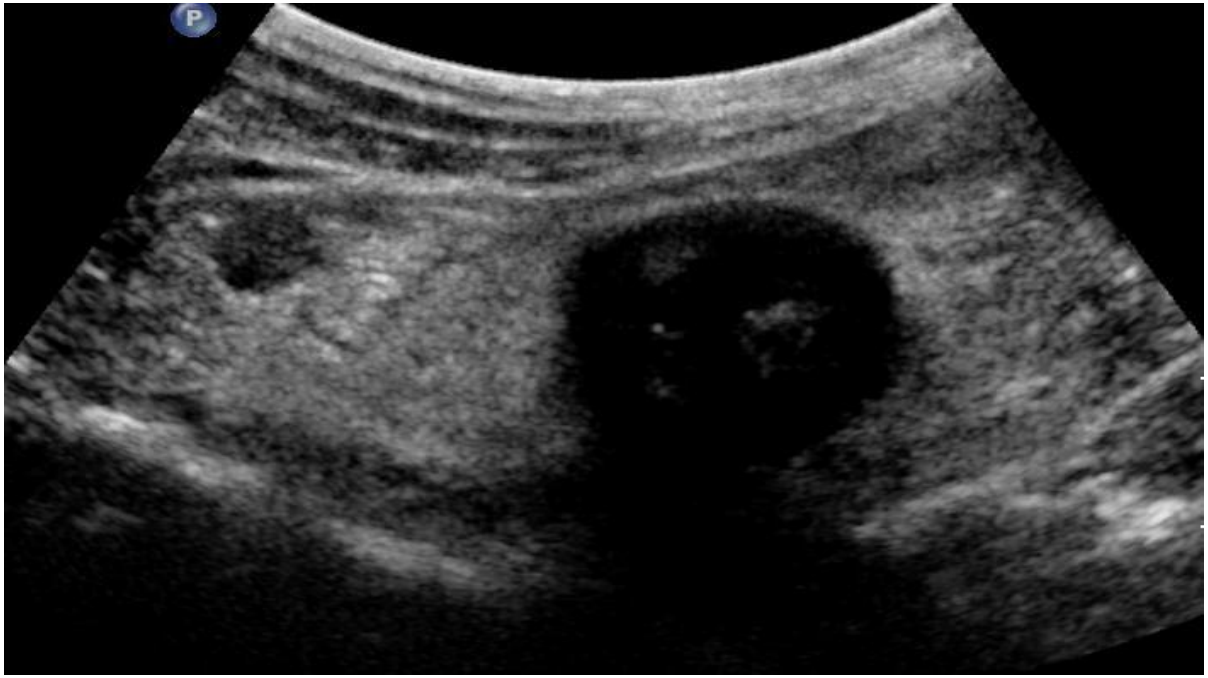

Color Doppler Signal

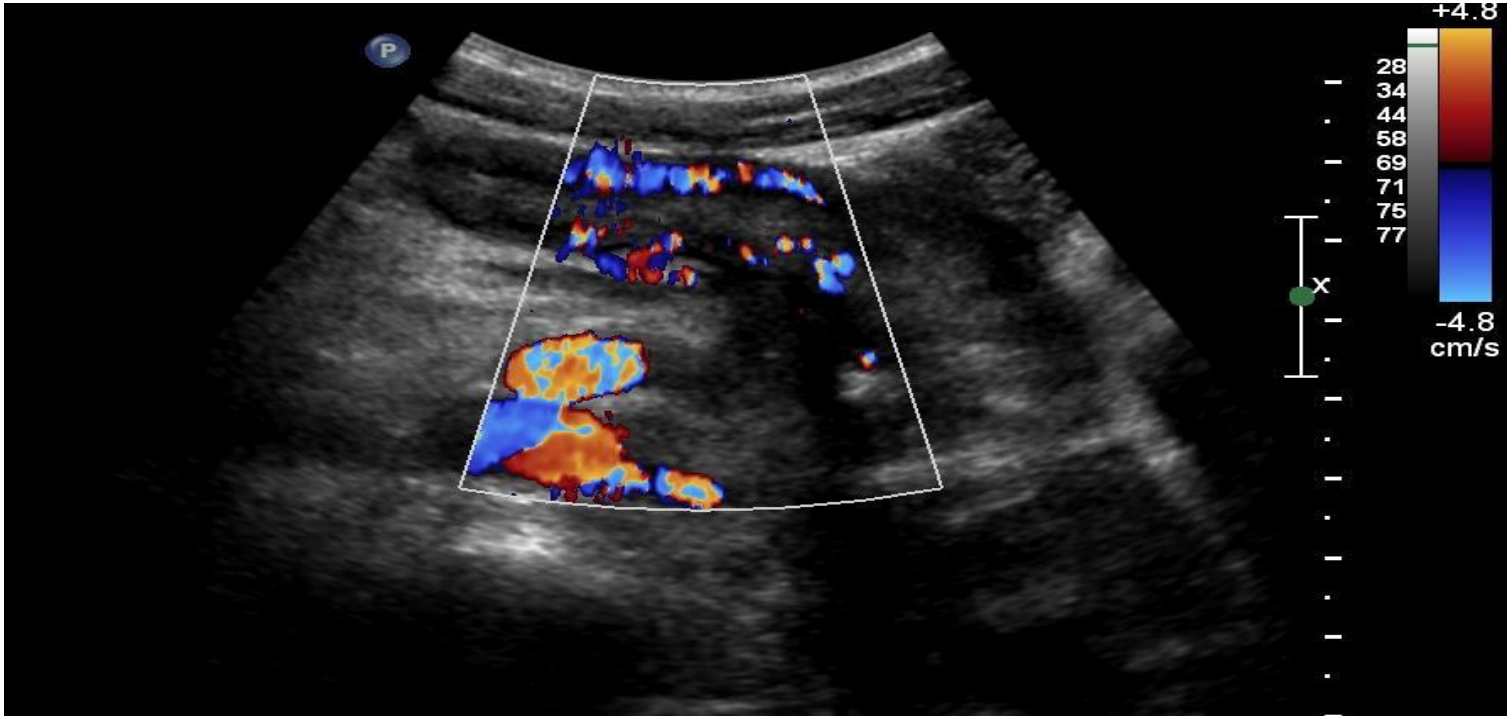

High intramural vascularization

Lymph Nodes

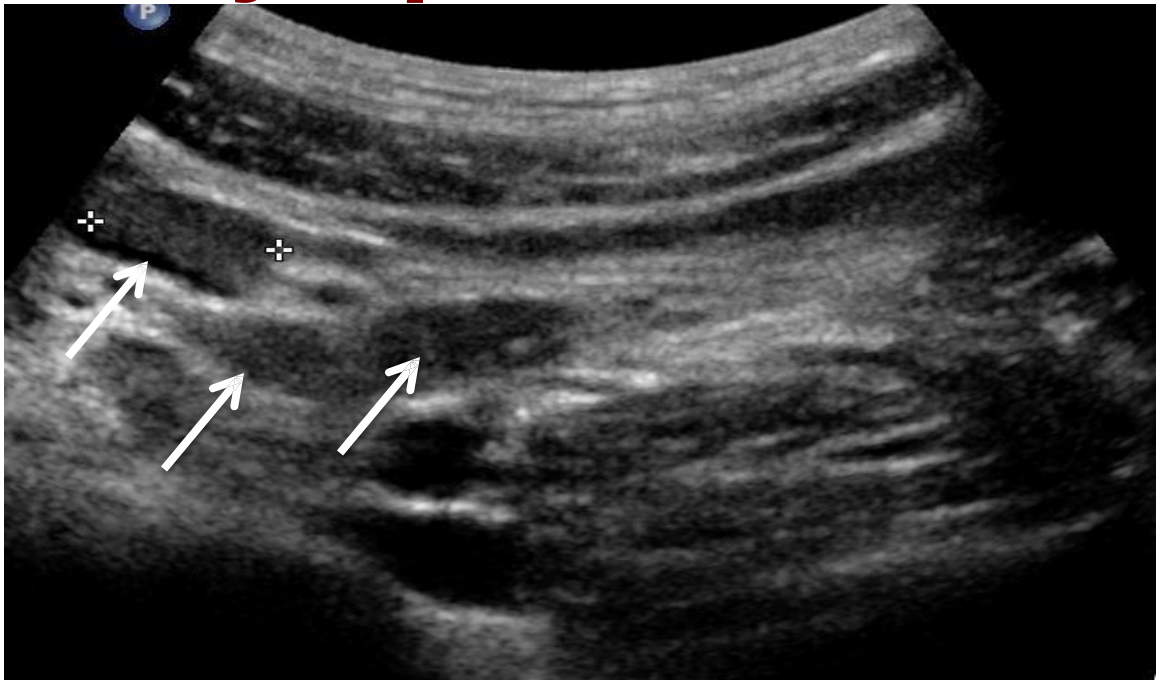

Simple Ultrasonographic Score

Bowel Wall Thickness

Mesenteric Inflammatory Fat

Lymph nodes

Complications

Novak et al. UEGW 2015; DDW 2016

IBD Complications on Bowel US

- Strictures
- Perforation
- Abscess/Phlegmon
- Fistulas

Stricture

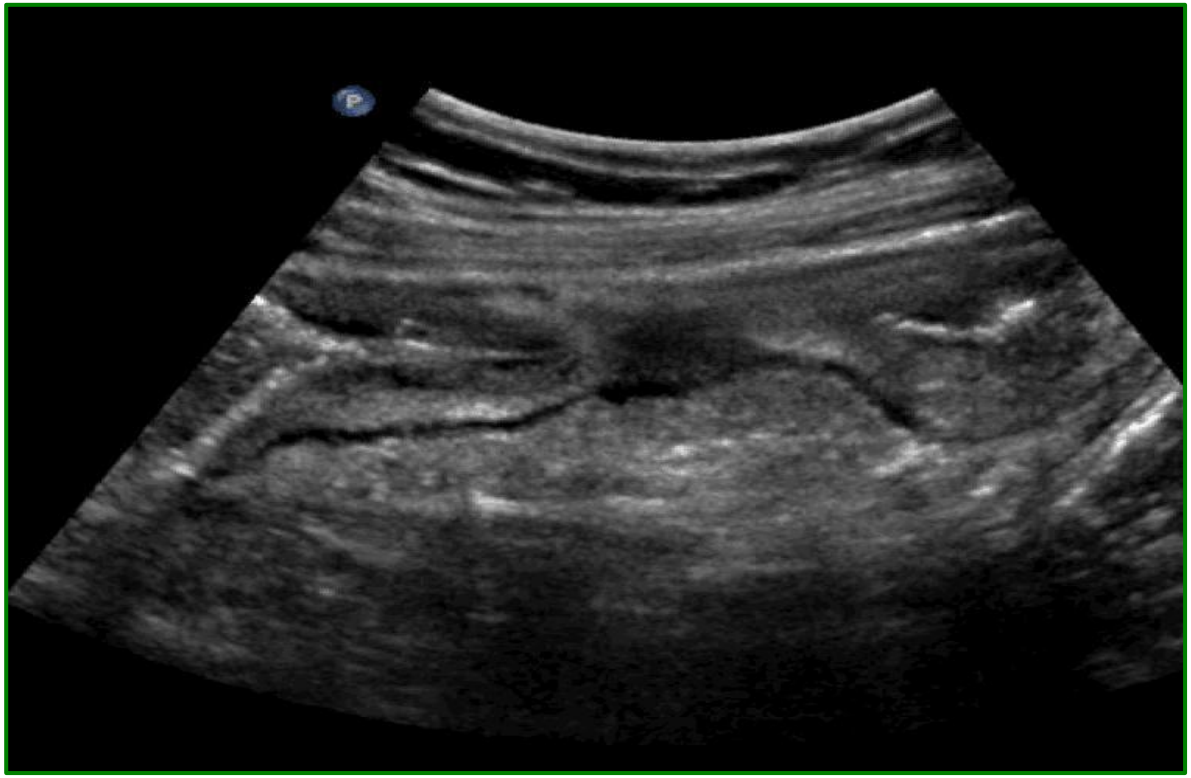

Abnormal Peristalsis

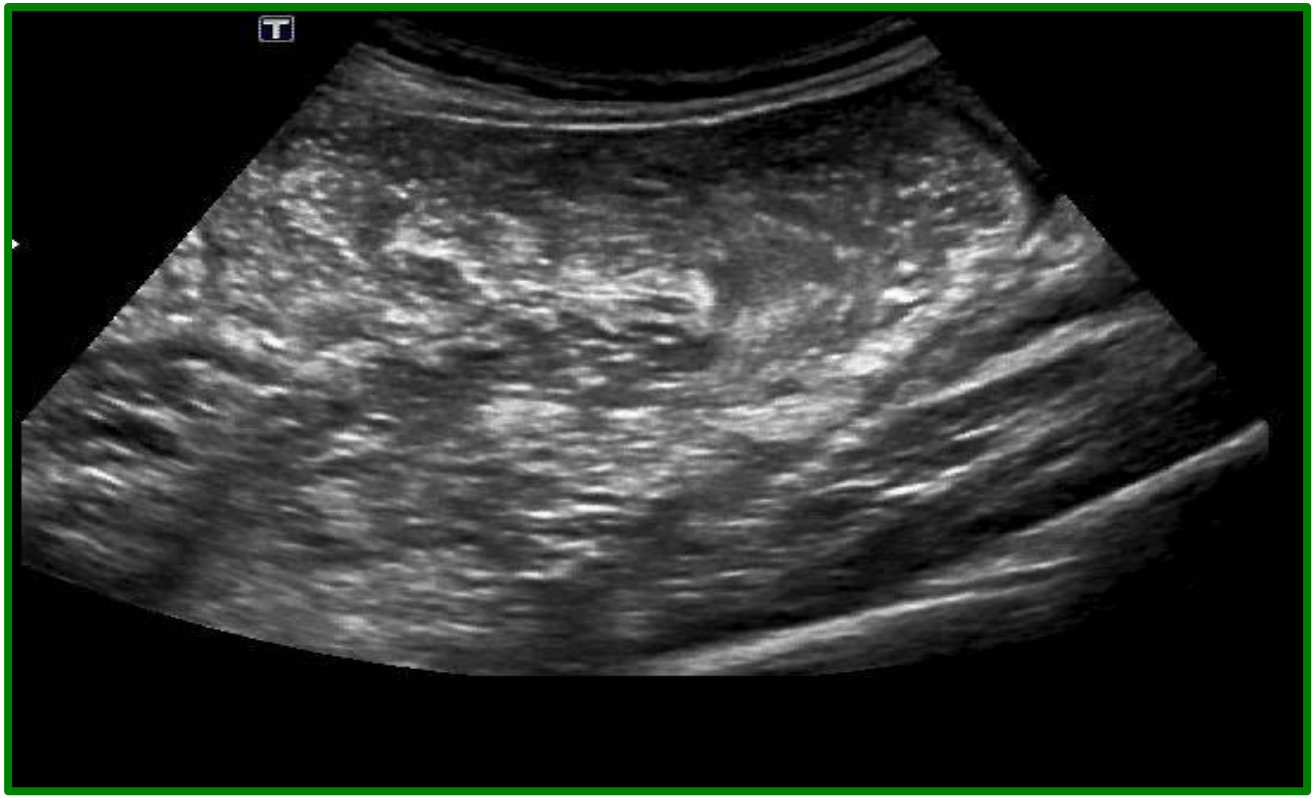

Phlegmon

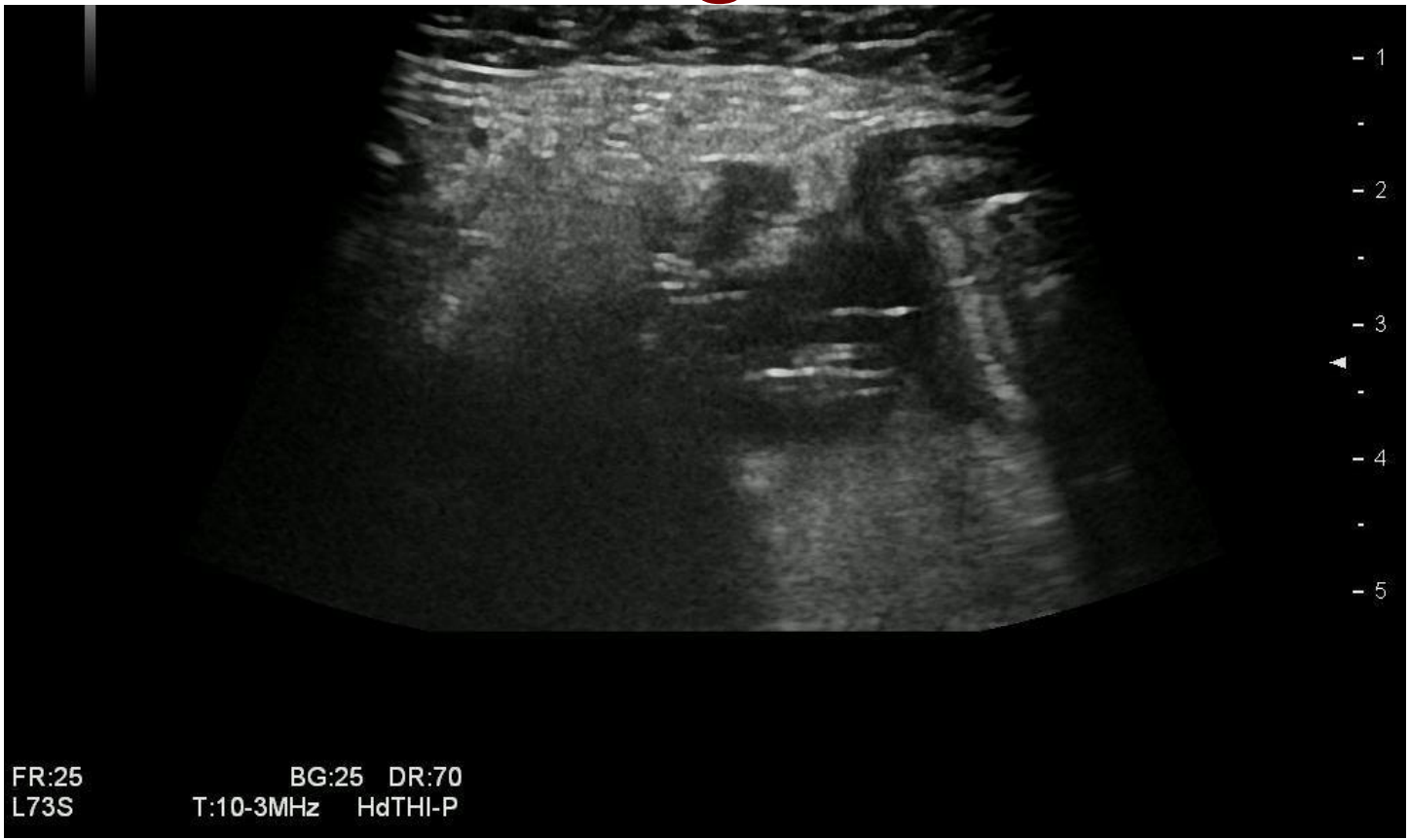

Fistula Tracts

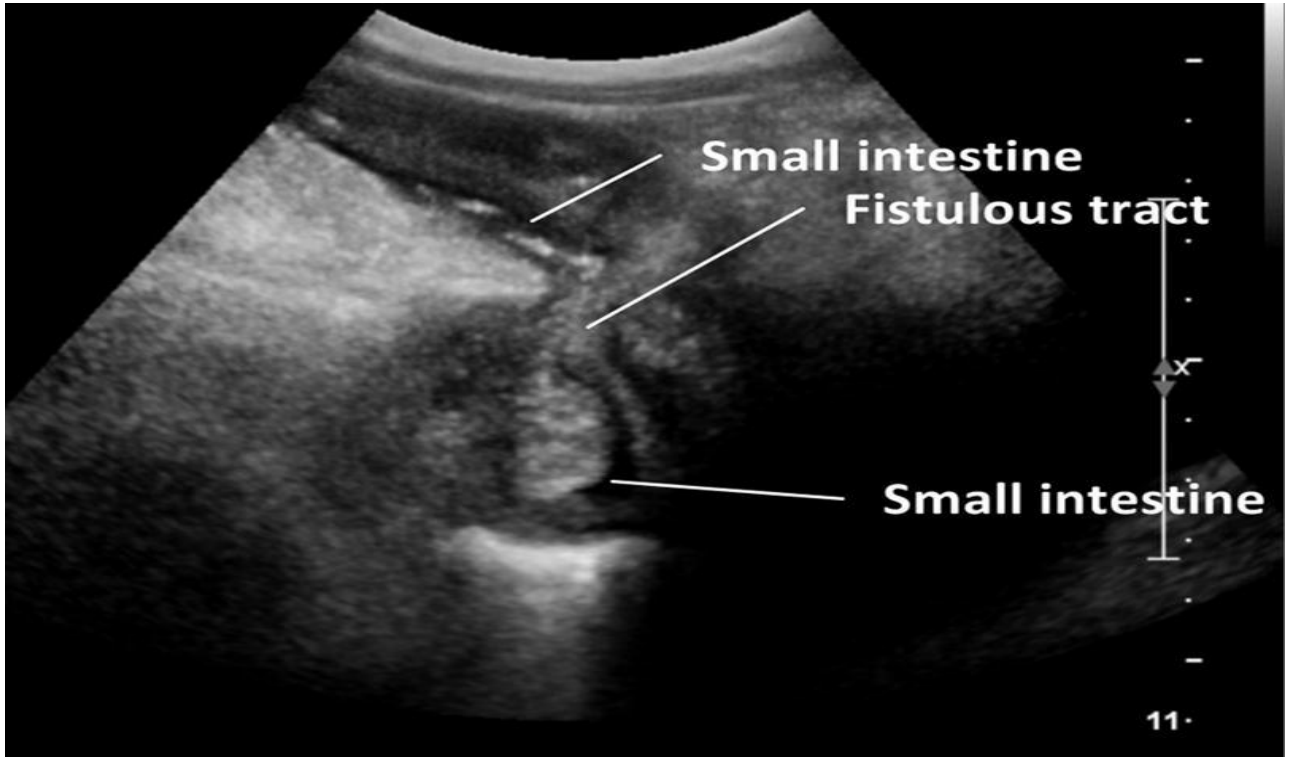

Objective #3

- Understand how imaging & ultrasound influences clinical decision-making

Case Example – Mr. EG

- 50 yo male with CD for 30 years treated only with occasional prednisone (highly responsive), no other medications, smoker
- 1 prior ileocecal resection (early 90’s)

Currently feeling well, however last on steroid within the year given obstructive symptoms.

Mr. EG

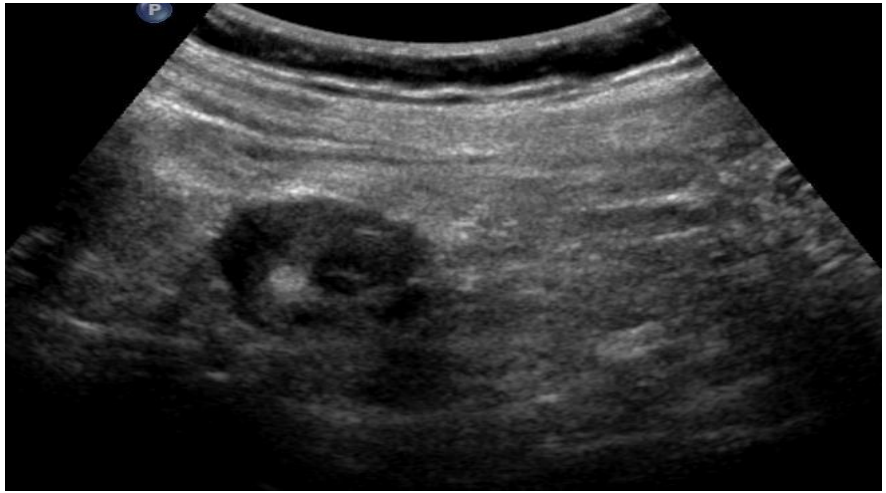

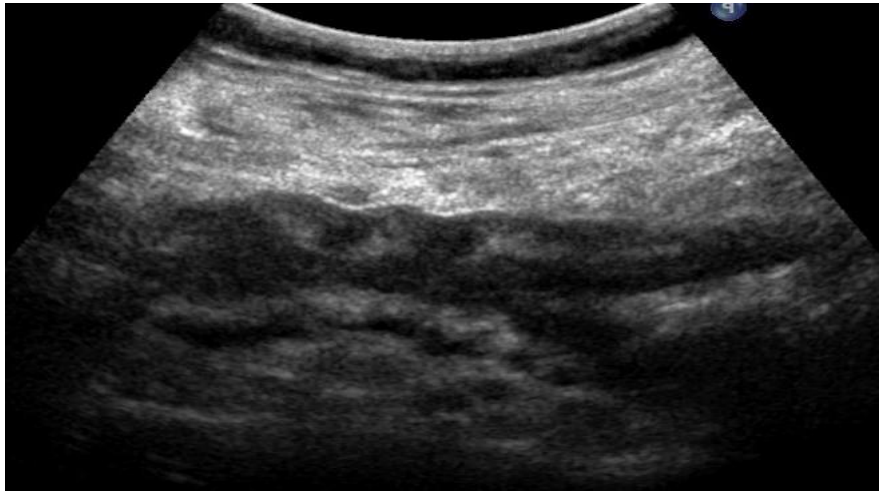

SR Wilson

Mr. EG: No Colour Doppler Signal

No blood flow - less likely significant inflammatory component of CD??

Trial biologic therapy – minimal improvement with obstructive symptoms returning

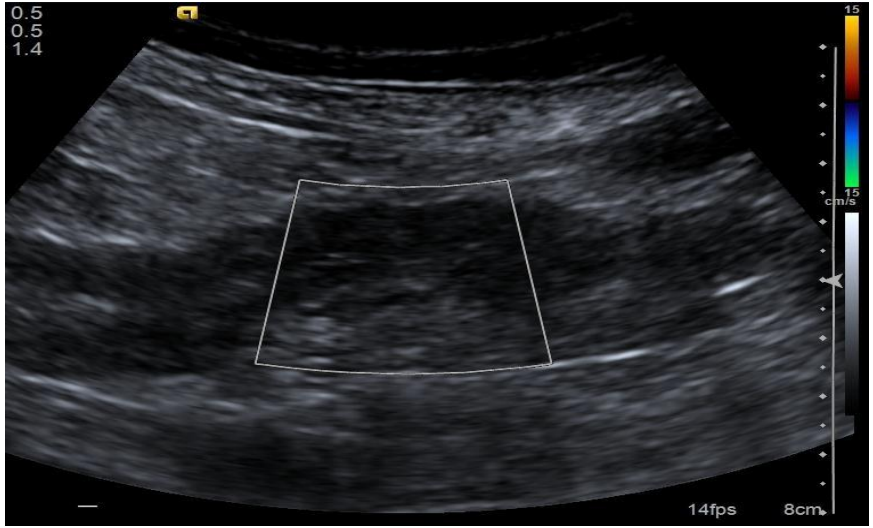

SR Wilson

Mr. EG: Low Blood Flow

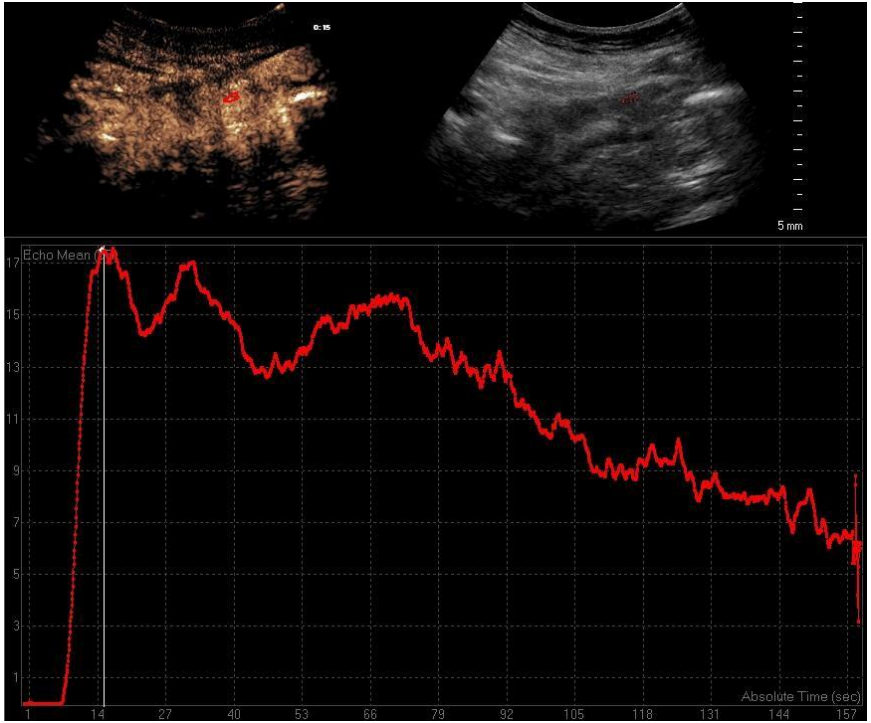

- Low CEUS peak enhancment: 17.5 dB

No activity < 15dB
Mild 15-18dB
Moderate 18db – 23dB
Severe > 23dB

SR Wilson

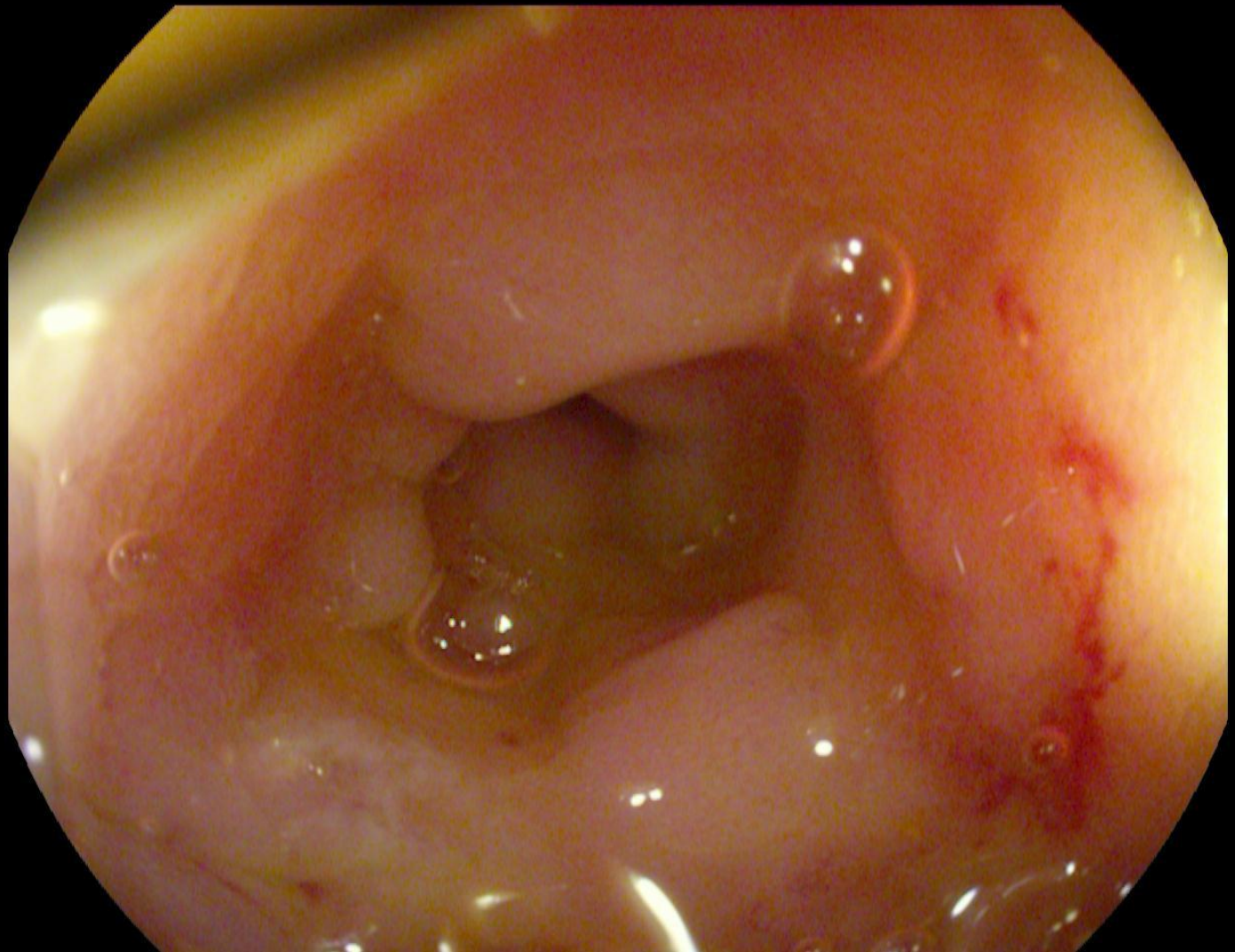

Mr. EG – Elastography

- High elastography parameters: 3.5 – 4.6 m/s suggesting hard fibrotic tissue

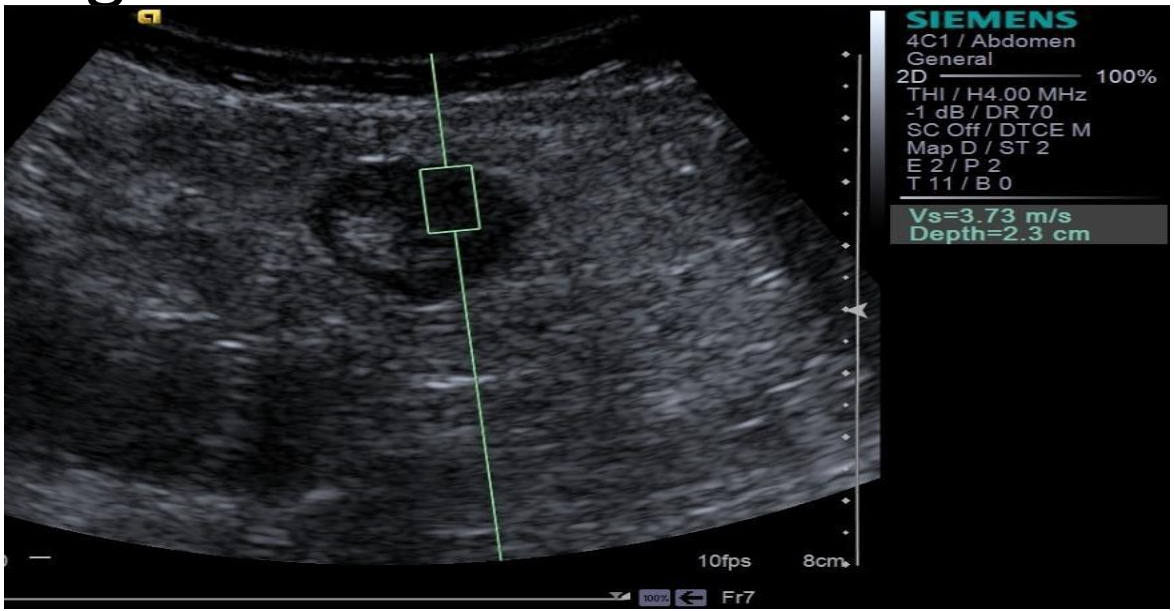

SR Wilson

Normal Ileal mucosa – muscularis mucosa and submucosa

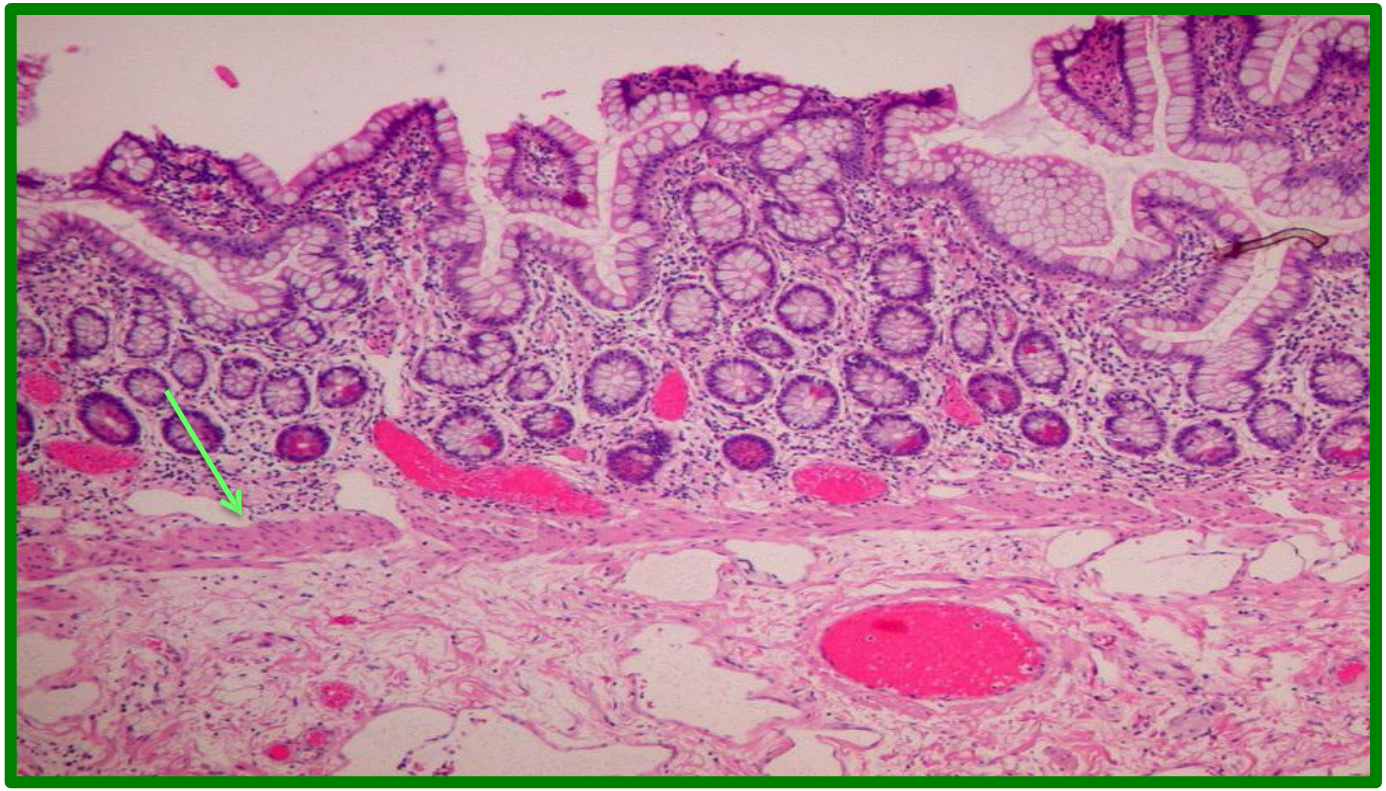

Chronic Stricture with Wall Muscularization

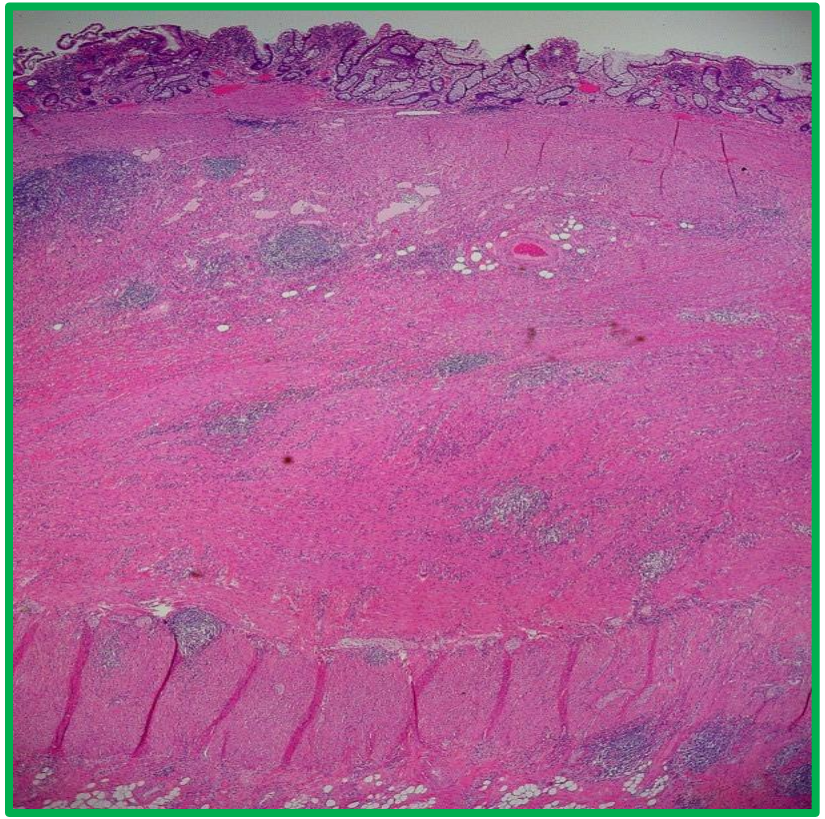

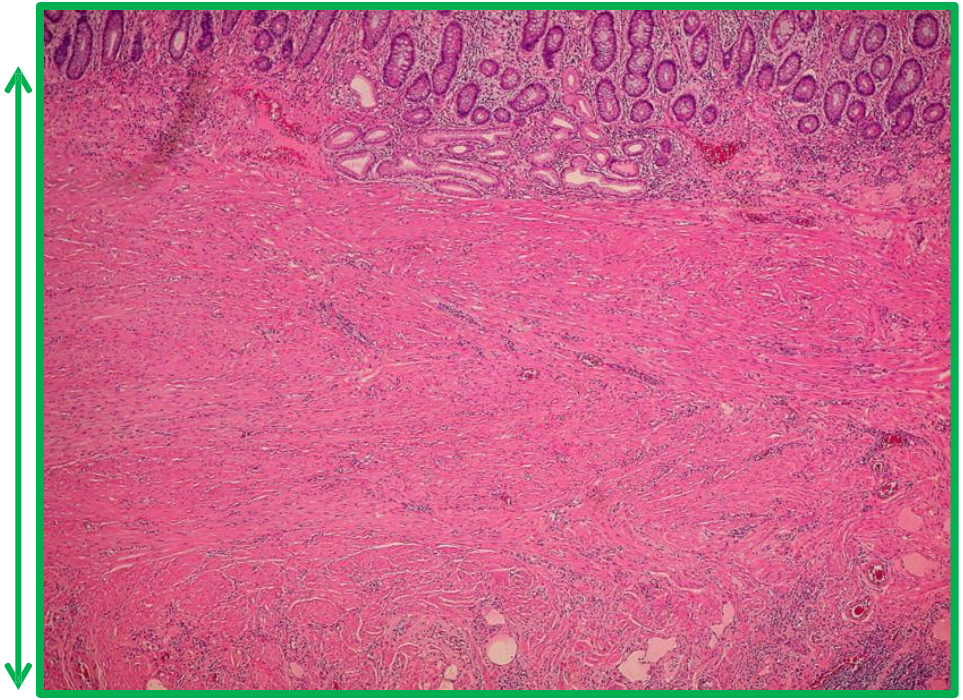

3 Months Post Resection

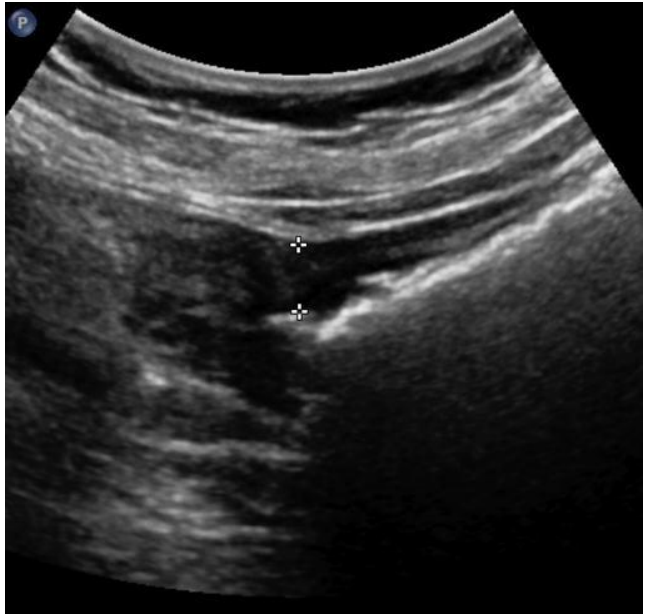

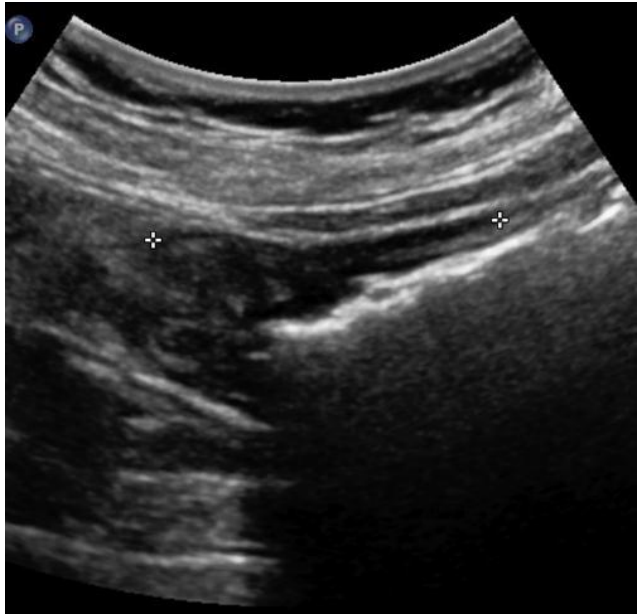

Early recurrence of CD in neo terminal ileum in longitudinal and axial view with bowel wall thickness of 7.7 mm and length of 4cm.

Color Doppler Intensity

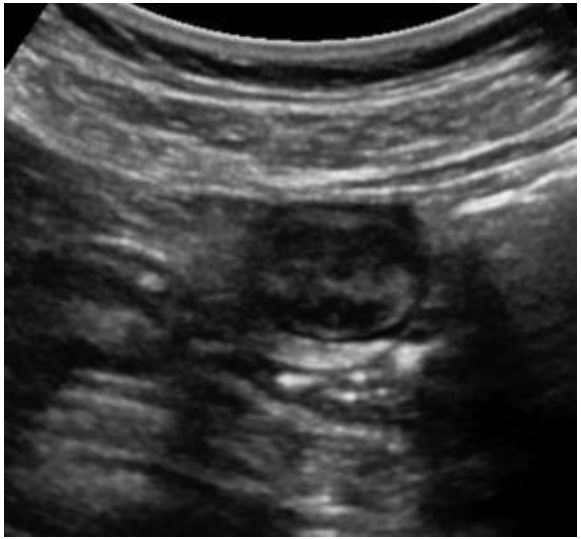

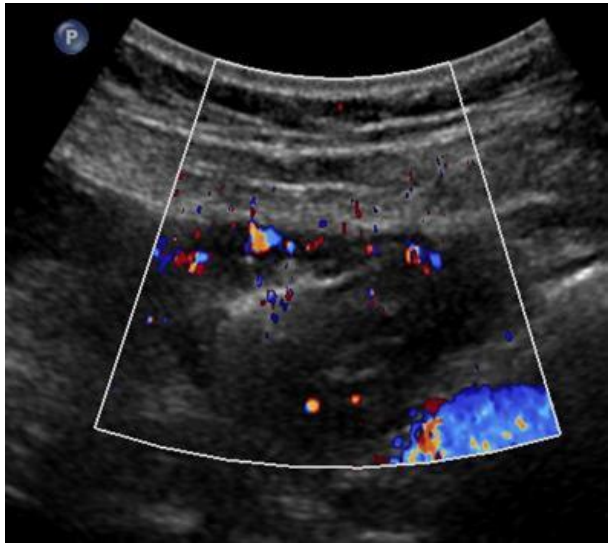

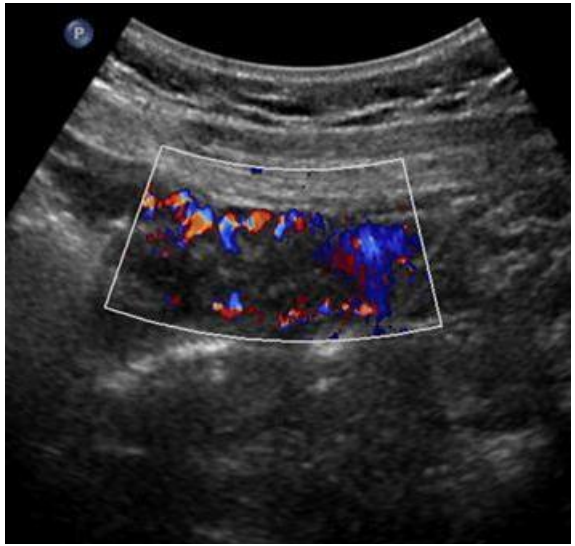

SR Wilson

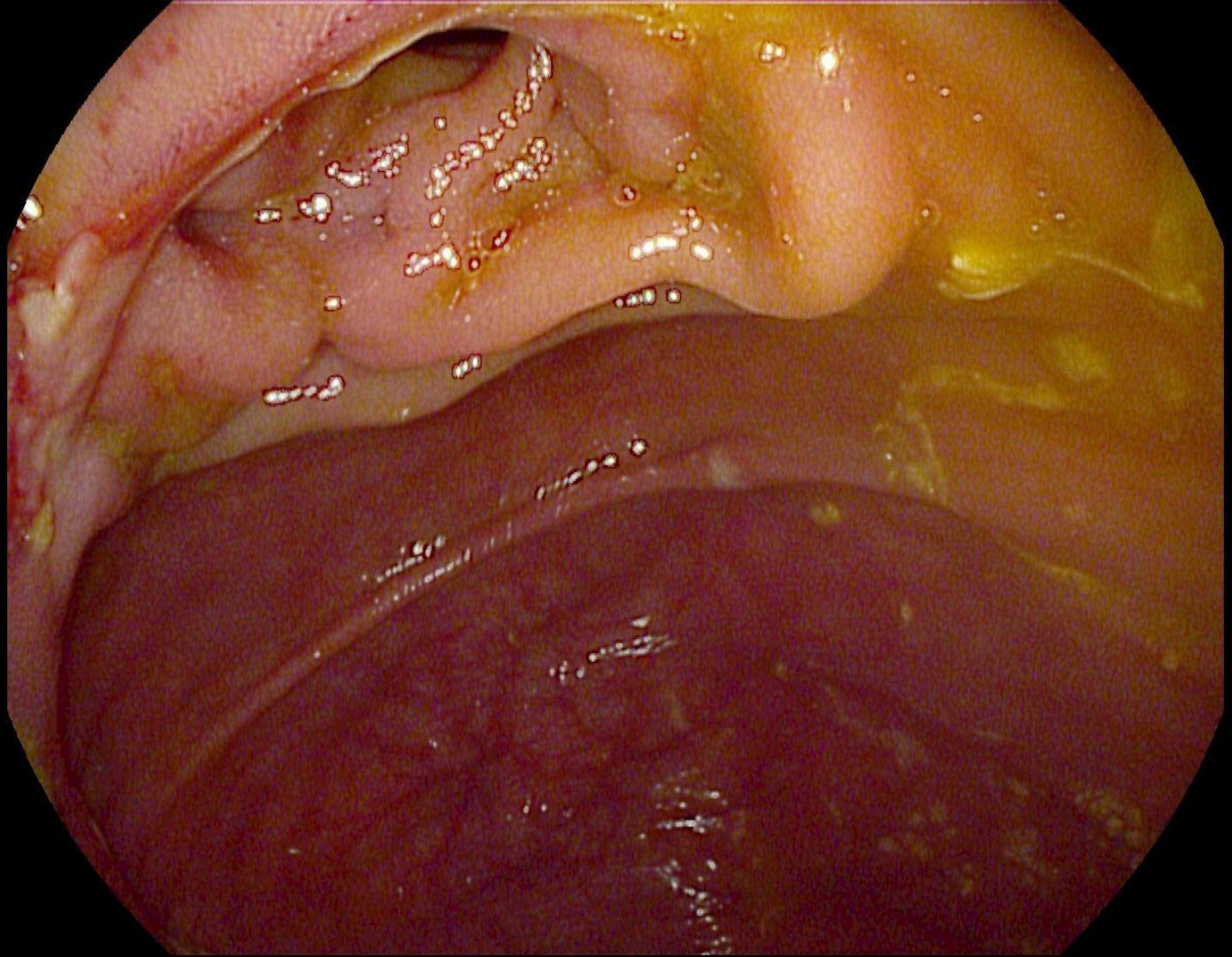

Objective #4

- Discuss other applications of US in clinic, by GI – useful as a clinical tool to differentiate between IBS and IBD in patients referred for symptoms such as diarrhea

Irritable Bowel Syndrome

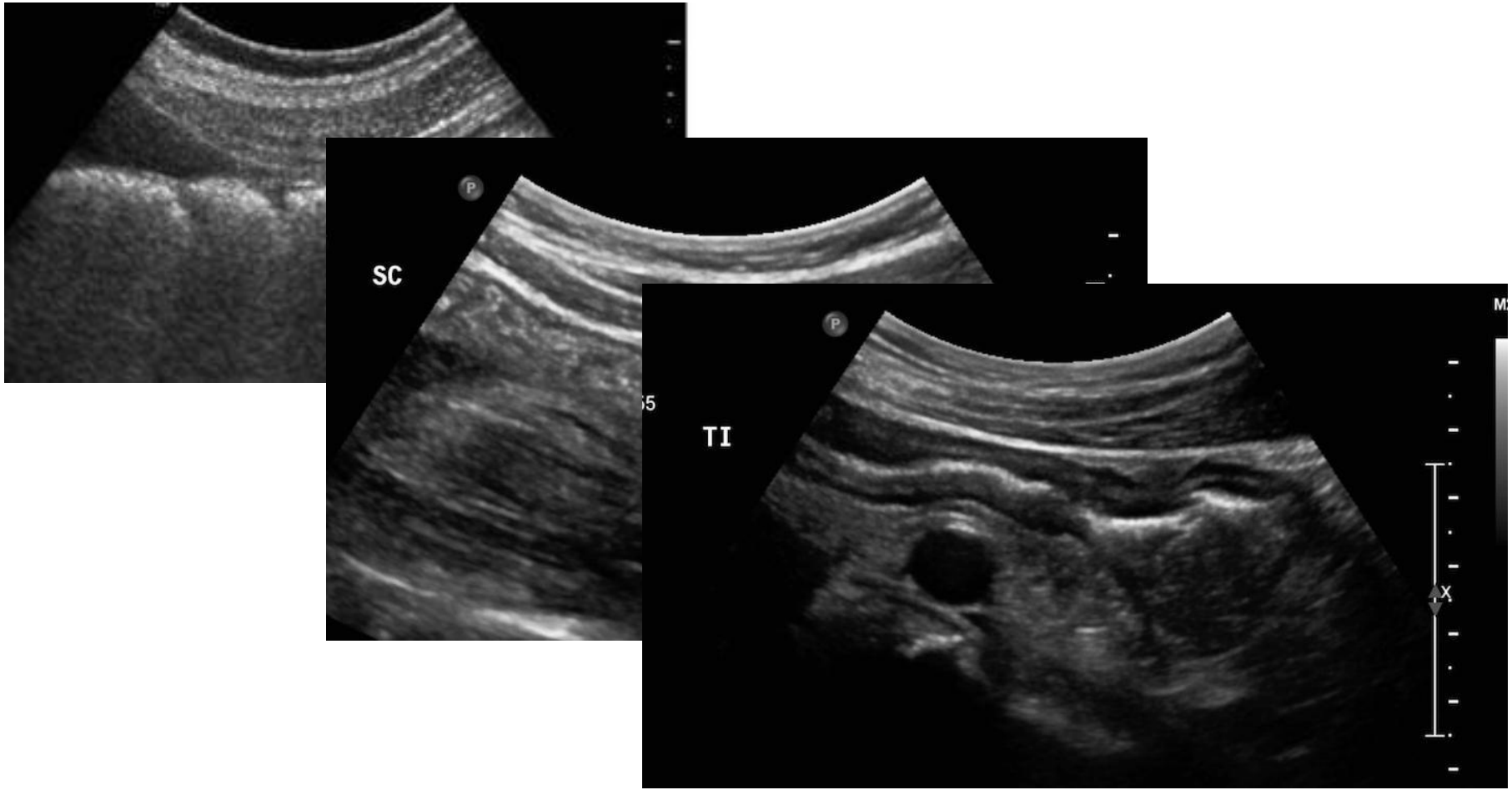
SC
TI

Sensitivity 80%
Specificity 98%
Positive Predictive Value 89%
Negative Predictive Value 96%

Novak, K 2015 CJG November

Thank You and Acknowledgements

- Dr. Stephanie Wilson
- Dr. Remo Panaccione
- Dr. Richard Fedorak

Evaluation and Certificate of Attendance

Please visit the CAG website at http://www.cag-acg.org/ to complete the session evaluation and to receive your certificate of attendance.

Or better yet, download the CDDW™ App from the CAG website!