High Resolution Esophageal Manometry

Dr. Geoffrey Turnbull MD, FRCPC

Dalhousie University

Dr. Yvonne Tse MD, FRCPC

University of Toronto

Name: Dr. Geoffrey Turnbull

Conflict of Interest Disclosure

(over the past 24 months)

Commercial or Non-Profit Interest	**Relationship**
Medtronic	Speaker, consultant
Allergan	Speaker

Name: Dr. Yvonne Tse

Conflict of Interest Disclosure

(over the past 24 months)

Commercial or Non-Profit Interest	**Relationship**
Abbvie	Advisory board
Lupin Pharma Canada	Consultant

CanMEDS Roles Covered

X	**Medical Expert** (as *Medical Experts*, physicians integrate all of the CanMEDS Roles, applying medical knowledge, clinical skills, and professional values in their provision of high-quality and safe patient-centered care. *Medical Expert* is the central physician Role in the CanMEDS Framework and defines the physician's clinical scope of practice.)
	Communicator (as Communicators, physicians form relationships with patients and their families that facilitate the gathering and sharing of essential information for effective health care.)
	Collaborator (as *Collaborators*, physicians work effectively with other health care professionals to provide safe, high-quality, patient-centred care.)
	Leader (as *Leaders*, physicians engage with others to contribute to a vision of a high-quality health care system and take responsibility for the delivery of excellent patient care through their activities as clinicians, administrators, scholars, or teachers.)
X	**Health Advocate** (as *Health Advocates*, physicians contribute their expertise and influence as they work with communities or patient populations to improve health. They work with those they serve to determine and understand needs, speak on behalf of others when required, and support the mobilization of resources to effect change.)
X	**Scholar** (as *Scholars*, physicians demonstrate a lifelong commitment to excellence in practice through continuous learning and by teaching others, evaluating evidence, and contributing to scholarship.)
	Professional (as *Professionals,* physicians are committed to the health and well-being of individual patients and society through ethical practice, high personal standards of behaviour, accountability to the profession and society, physician-led regulation, and maintenance of personal health.)

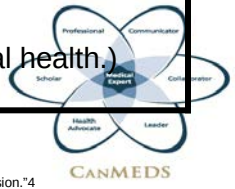

Learning objectives

At the end of this session, participants will be able to:

- Identify the role of high resolution esophageal manometry study in your clinical practice
- Utilize Chicago Classification when interpreting esophageal manometry study
- Apply esophageal manometry study in managing patients with dysphagia and other esophageal symptoms

Diagnostic approach to uninvestigated dysphagia

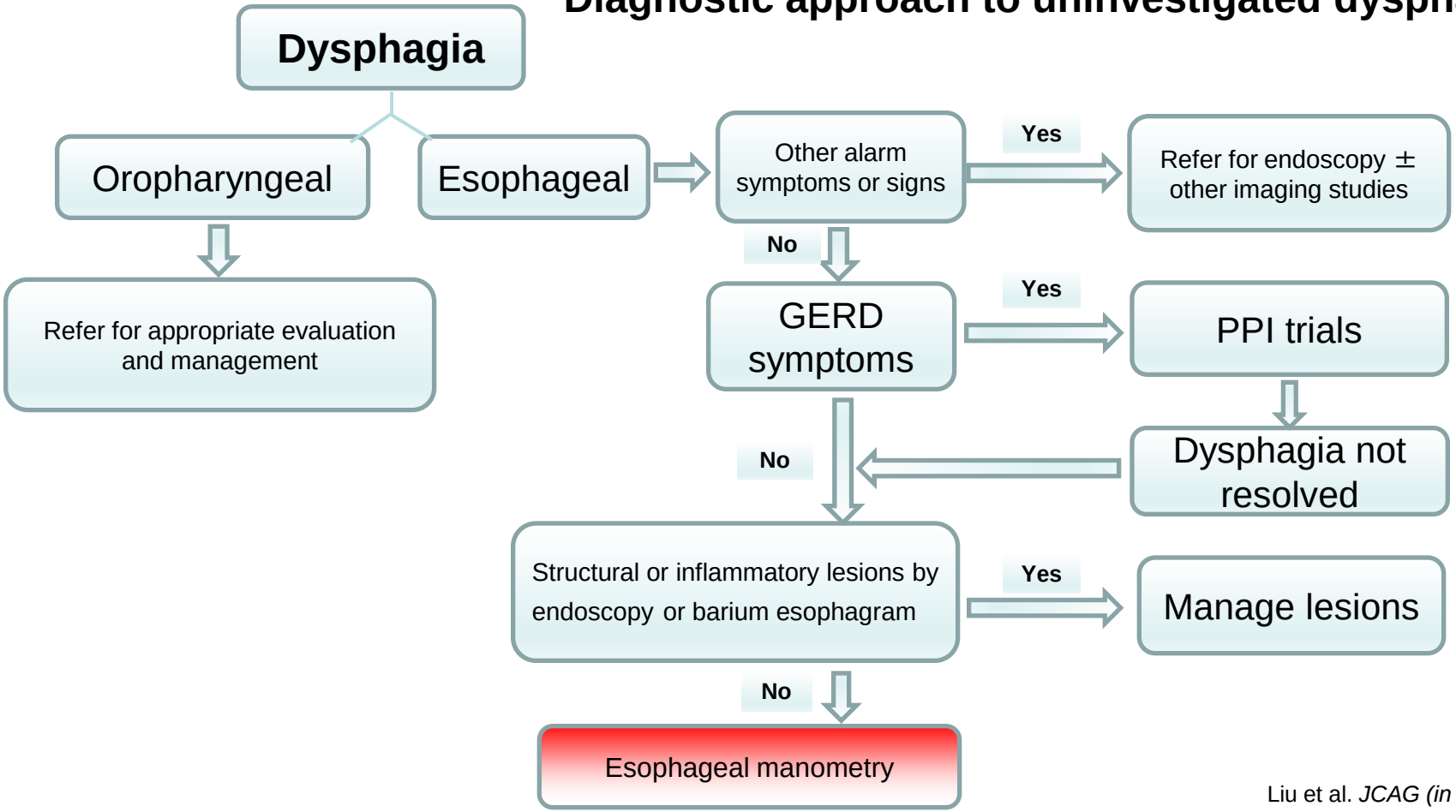

Liu et al. *JCAG (in press)*.

EMS is definitely indicated…

- To establish the diagnosis of dysphagia in the absence of mechanical obstruction (UGI series, endoscopy)
- For placement of intraluminal devices (e.g. pH probe) when positioning depends on the relationship to functional landmarks (esp. LES)
- For the pre-op assessment for anti-reflux surgery to exclude other primary esophageal dysmotility

Pandolfino et al. Gastroenterology 2005, 128, 209-224.

EMS is possibly indicated…

- For the pre-operative assessment of peristaltic function in patients being considered for antireflux surgery

- For evaluation of dysphagia in patients status post antireflux surgery or treatment for achalasia

Pandolfino et al. Gastroenterology 2005, 128, 209-224.

EMS is contraindicated…

- For confirming a suspected diagnosis of GERD
- As the initial test for chest pain or other esophageal symptoms because of the low specificity of the findings and the low likelihood of detecting a clinically significant motility disorder

Pandolfino et al. Gastroenterology 2005, 128, 209-224.

Neurogastroenterology & Motility

Neurogastroenterol Motil (2015) **27**, 160–174 doi: 10.1111/nmo.12477

The Chicago Classification of esophageal motility disorders, v3.0

P. J. KAHRILAS, A. J. BREDENOORD, M. FOX, C. P. GYAWALI, S. ROMAN, A. J. P. M. SMOUT, J. E. PANDOLFINO & INTERNATIONAL HIGH RESOLUTION MANOMETRY WORKING GROUP*

Department of Medicine, Feinberg School of Medicine, Northwestern University, Chicago, IL, USA

Chicago Classification analysis

- Based on assessment of individual swallows (10 x 5 mL)
- Hierarchical approach
- Two basic steps when looking at manometry study:
  1. Evaluate the function of Integrated Residual Pressure (IRP) of LES
     - *Presence or absence of relaxation*
  2. Evaluate peristaltic abnormalities
     - *Amplitude of contractions*
     - *“Pattern” of contractions*

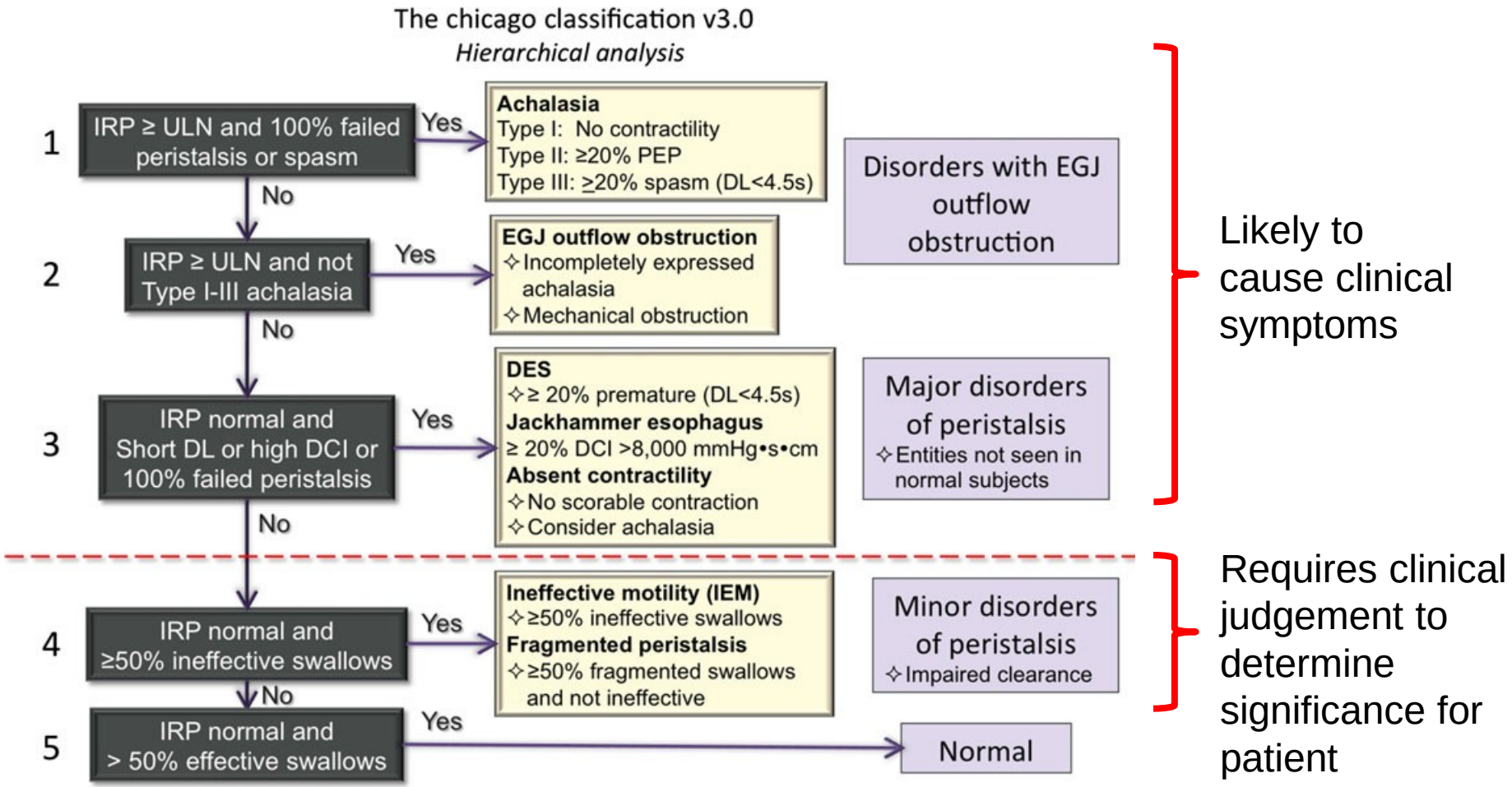

Kahrilas et al. Neurogastrol Motil 2015

Conventional manometry and high resolution manometry with esophageal pressure topography

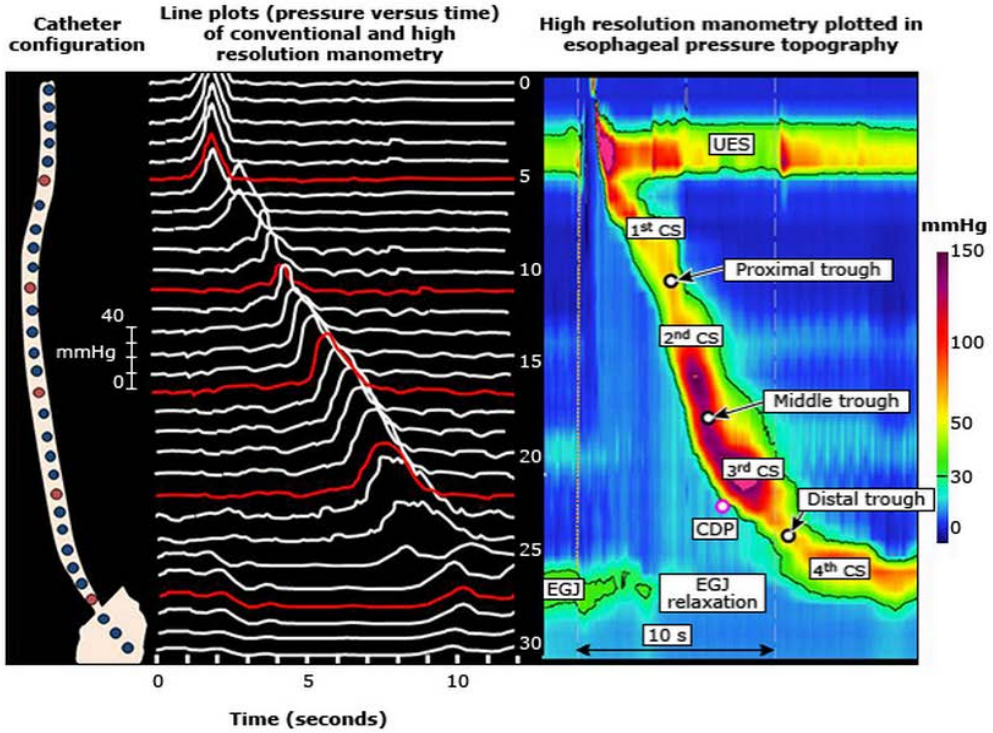

UES: Upper esophageal sphincter
LES: Lower esophageal sphincter
CDP: Contractile deceleration point
EGJ: Esophagogastric junction
CS: Contractile segment
- 1st: UES
- 2nd & 3rd: Esophageal body
- 4th: LES

Transition zone = pressure between 1st & 2nd CS

Kahrilas et al. Neurogastrol Motil 2015
High resolution manometry, UpToDate 2015, Graphic 86104 Version 2.0

Principal Parameters for Chicago Classification v. 3.0

		Normal
IRP (4 sec; mmHg)	Integrated Relaxation Pressure	*< 15 mmHg**
CDP (time, position)	Contractile Deceleration Point	
DL (sec)	Distal Latency	*> 4.5 sec*
DCI (mmHg-cm-sec)	Distal Contractile Integral	*450-8000**
Pattern	Fragmentation	*Break > 5 cm in 20 mmHg isobaric contour*

* = normal values used by Manoview

Kahrilas et al. Neurogastrol Motil 2015

IRP of Lower Esophageal Sphincter

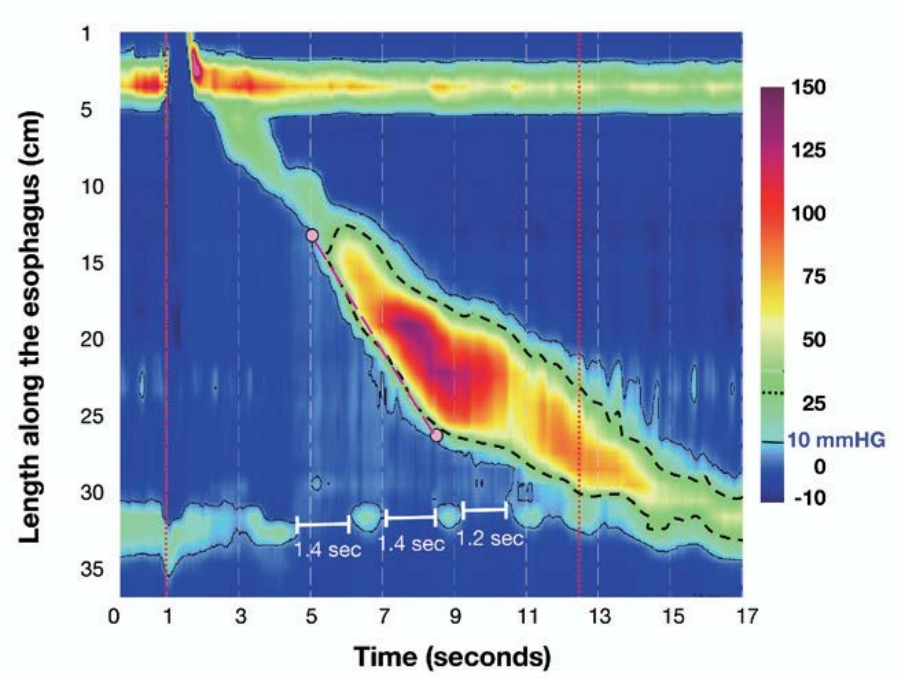

Median of the 4 s of maximal relaxation of the LES in the 10-s window beginning at UES relaxation

Pandolfino et al. Gastroenterology 2008

IRP of Lower Esophageal Sphincter

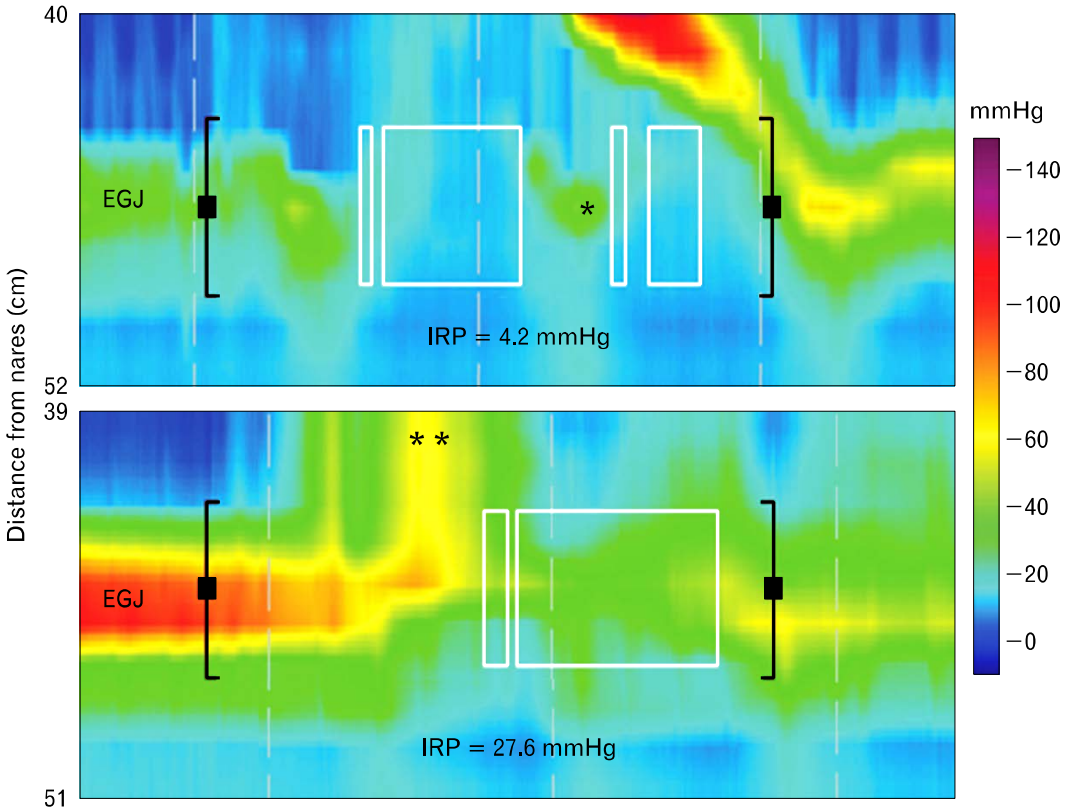

Contractile Deceleration Point (CDP) and Distal Latency (DL)

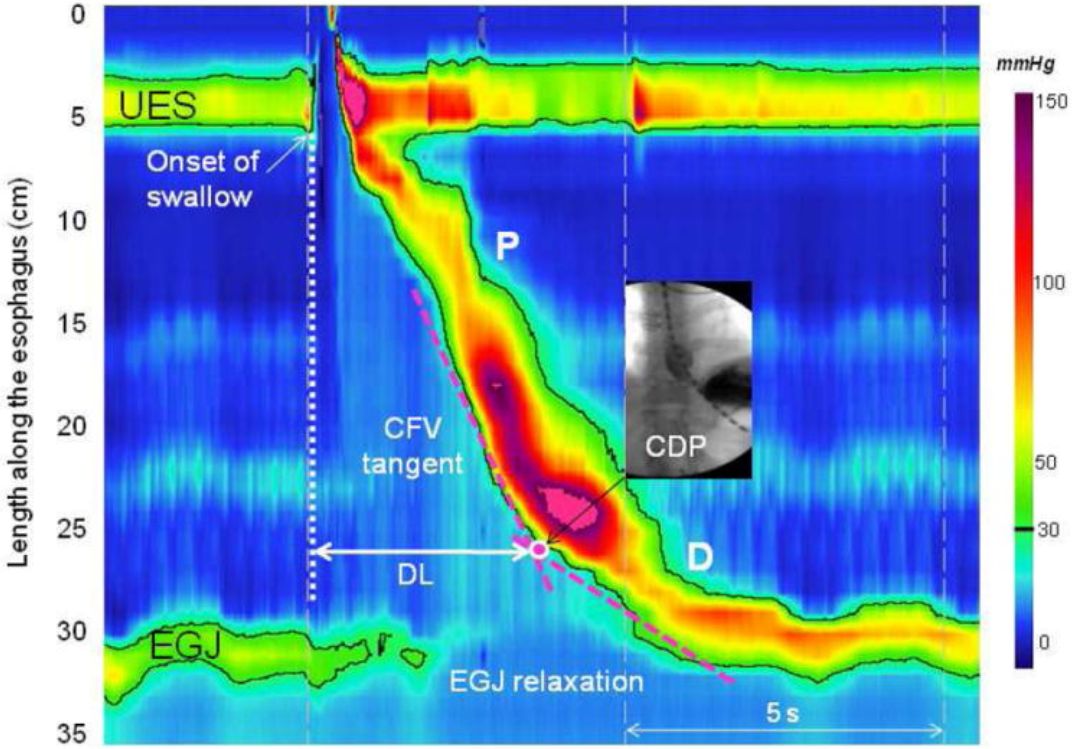

Pandolfino et al. Thorac Surg Clin 2011

Distal Contractile Integral (DCI)

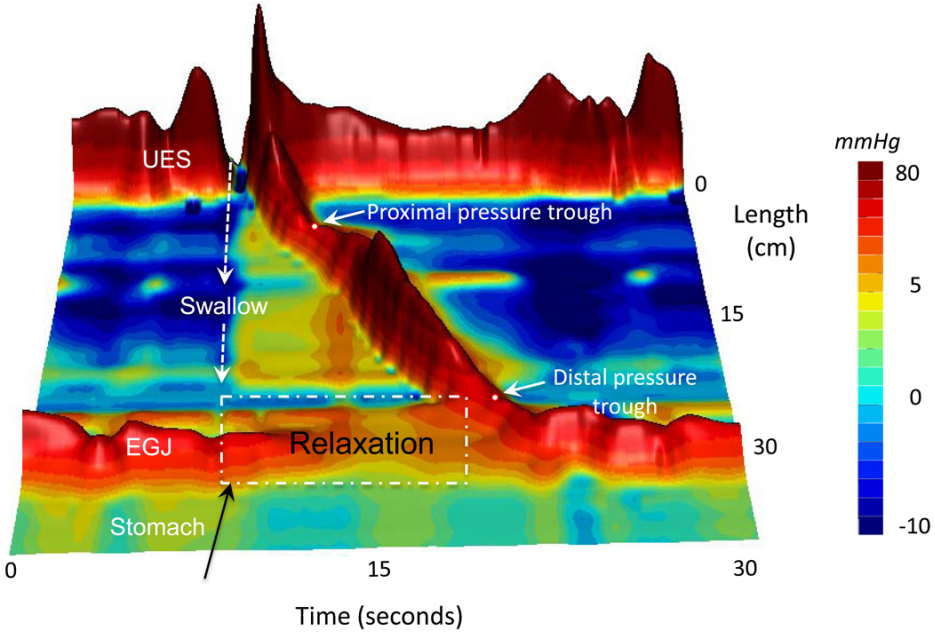

- Amplitude x Duration x Length (mmHg-s-cm) of any contraction exceeding 20 mmHg: from the **<u>transition zone</u>** *to* the **<u>proximal margin of the LES</u>**
- Summarizes the distal contractile vigor

Amplitude of Contractions

- ***Failed**:* DCI <100 mmHg-s-cm
- ***Weak:*** DCI >100 mmHg-s-cm, but <450 mmHg-s-cm

Ineffective

- ***Normal**:* DCI ≥ 450 mmHg-s-cm but ≤ 8000 mmHg-s-cm
- ***Hypercontractile**:* DCI > 8000 mmHg-s-cm

Kahrilas et al. Neurogastrol Motil 2015

“Pattern” of Contractions

- ***Premature:*** DL <4.5 s
- ***Fragmented:*** Large break (>5 cm length) in the 20-mmHg isobaric contour with DCI >450 mmHg-s-cm
- ***Intact:*** Not achieving the above diagnostic criteria

Kahrilas et al. Neurogastrol Motil 2015

Normal EMS

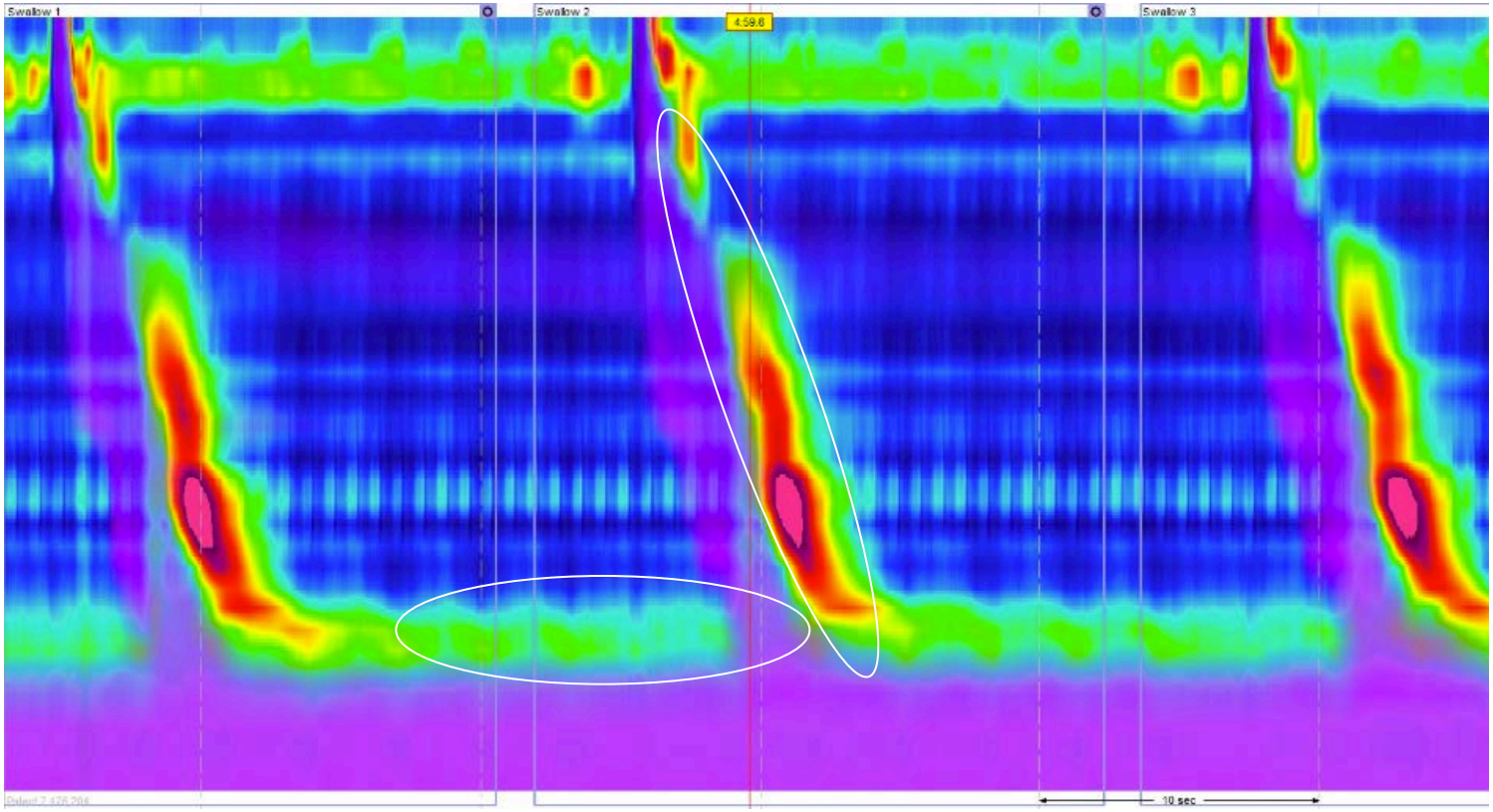

Pressure Topography Plot

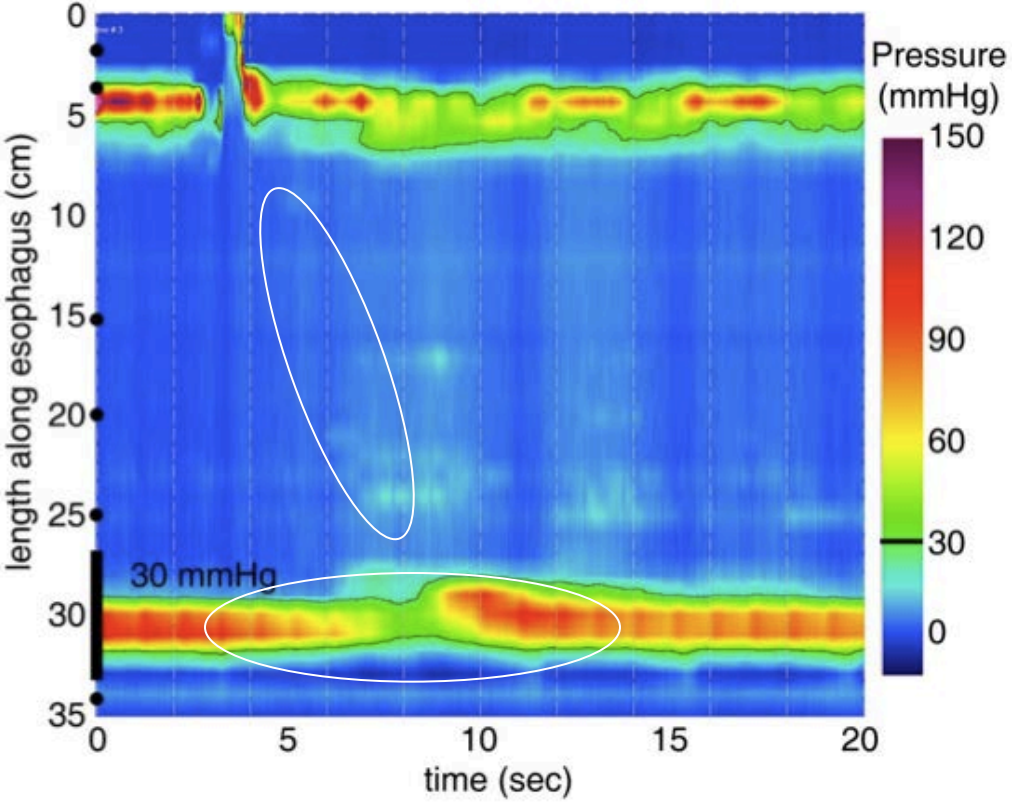

Pressure Topography Plot

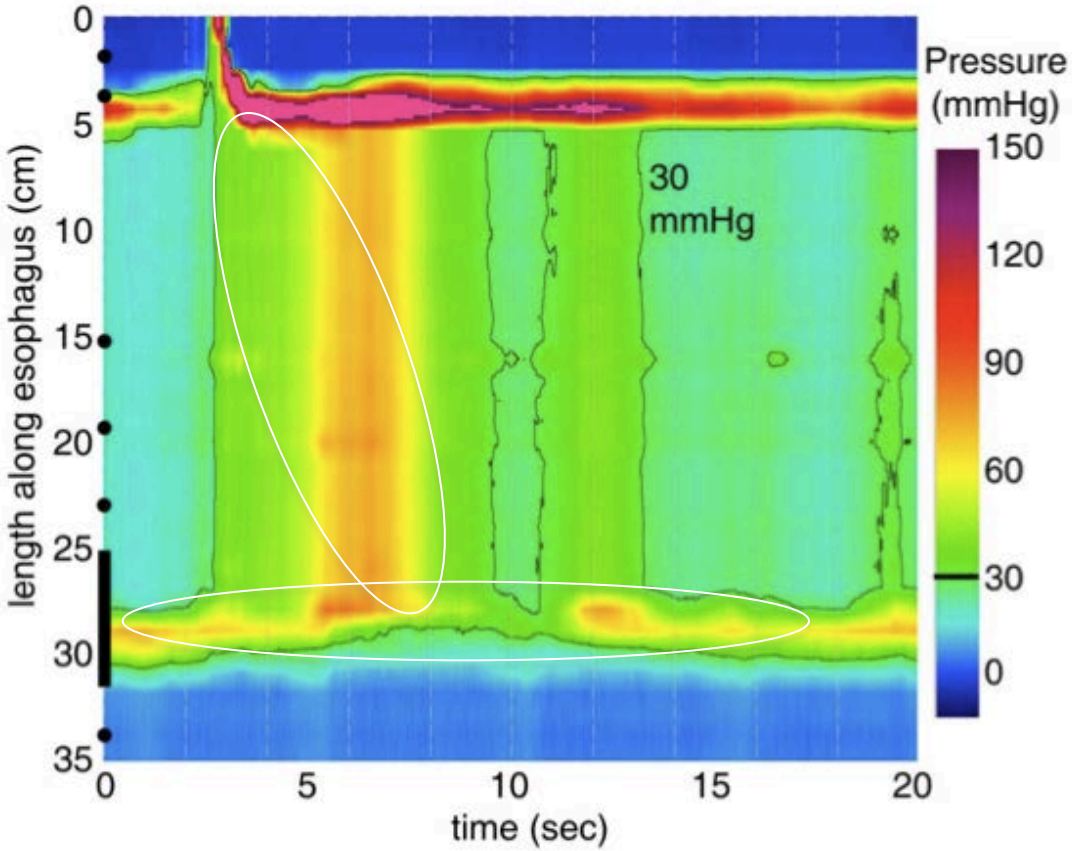

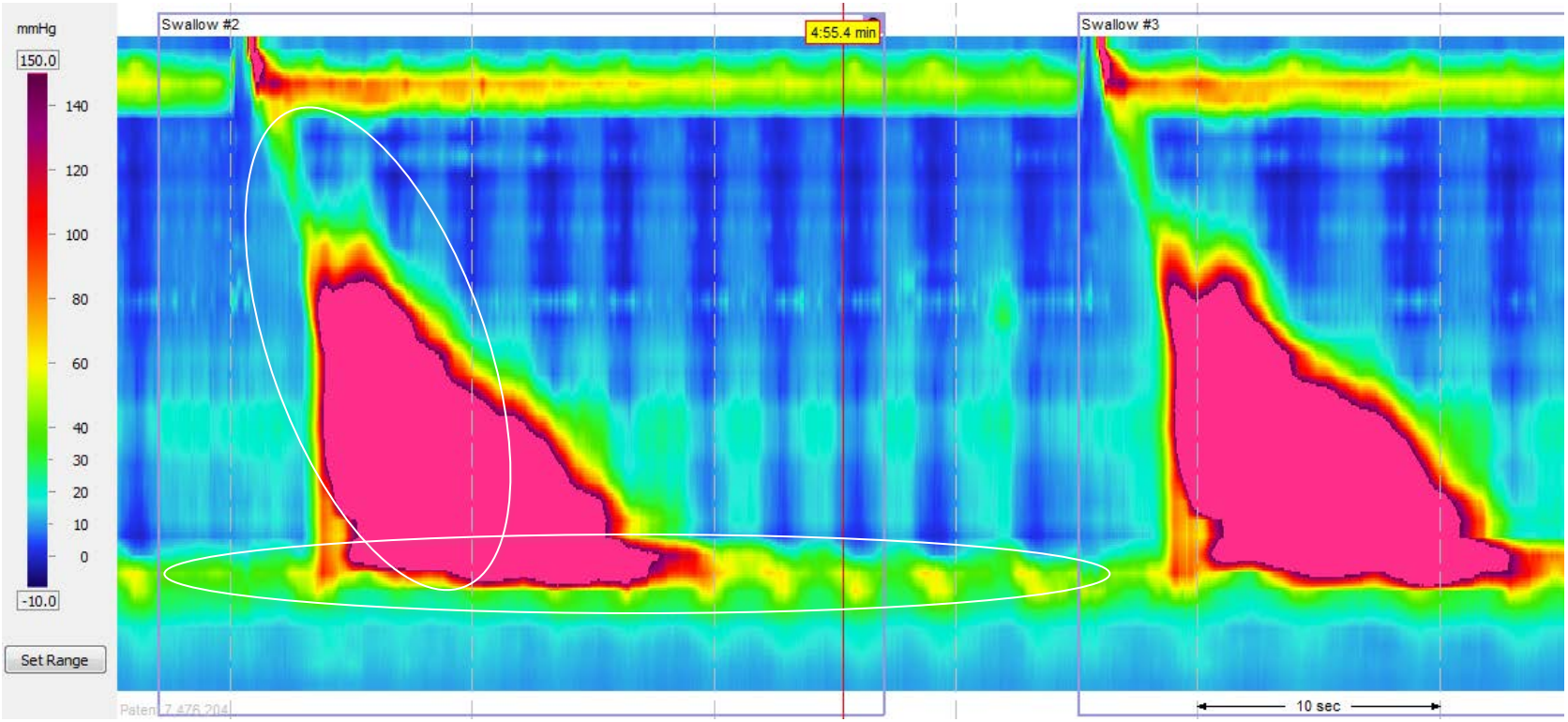
mmHg
150.0
140
120
100
80
60
40
30
20
10
0
-10.0
Set Range
Swallow #2
4:55.4 min
Swallow #3
10 sec

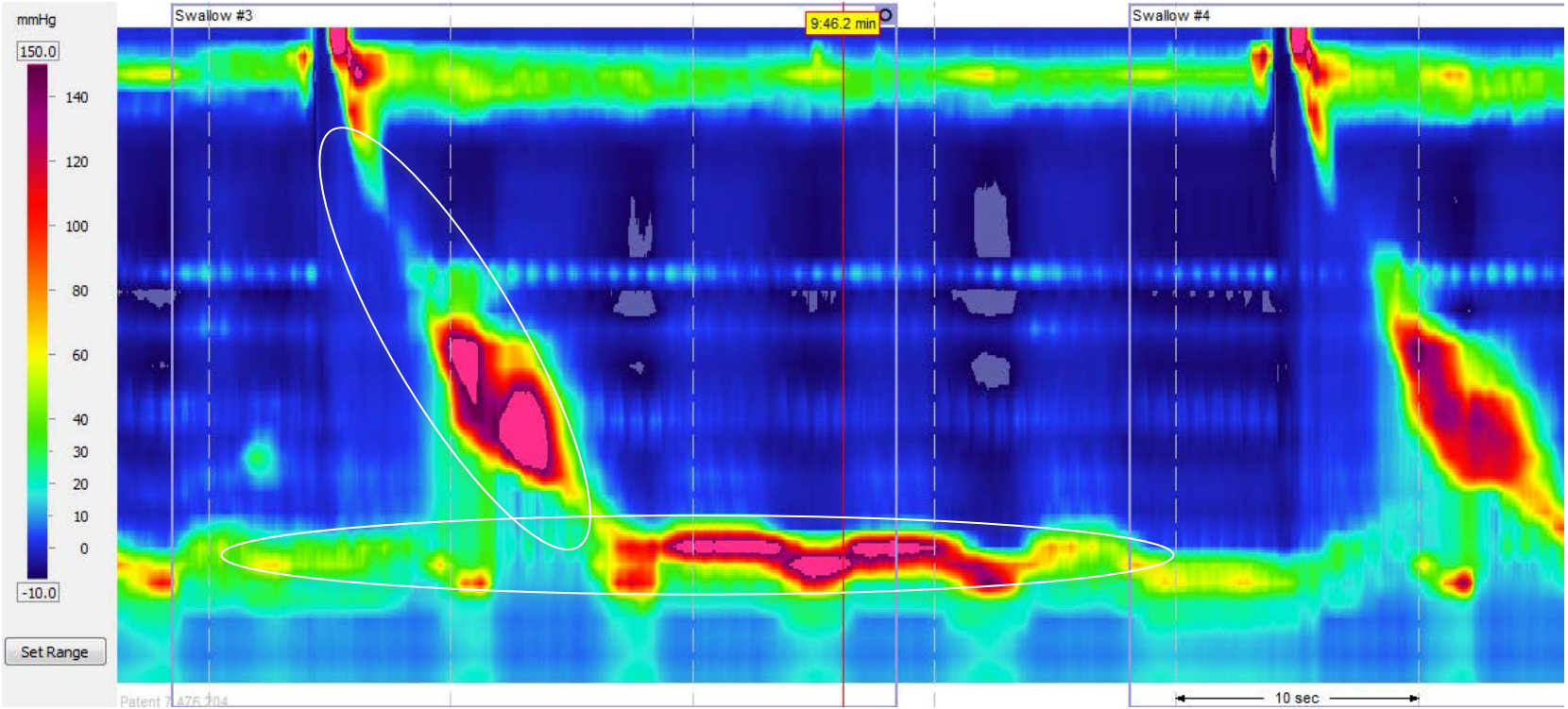
mmHg
150.0
140
120
100
80
60
40
30
20
10
0
-10.0
Set Range
Swallow #3
9:46.2 min
Swallow #4
10 sec
Patent 7,476,204

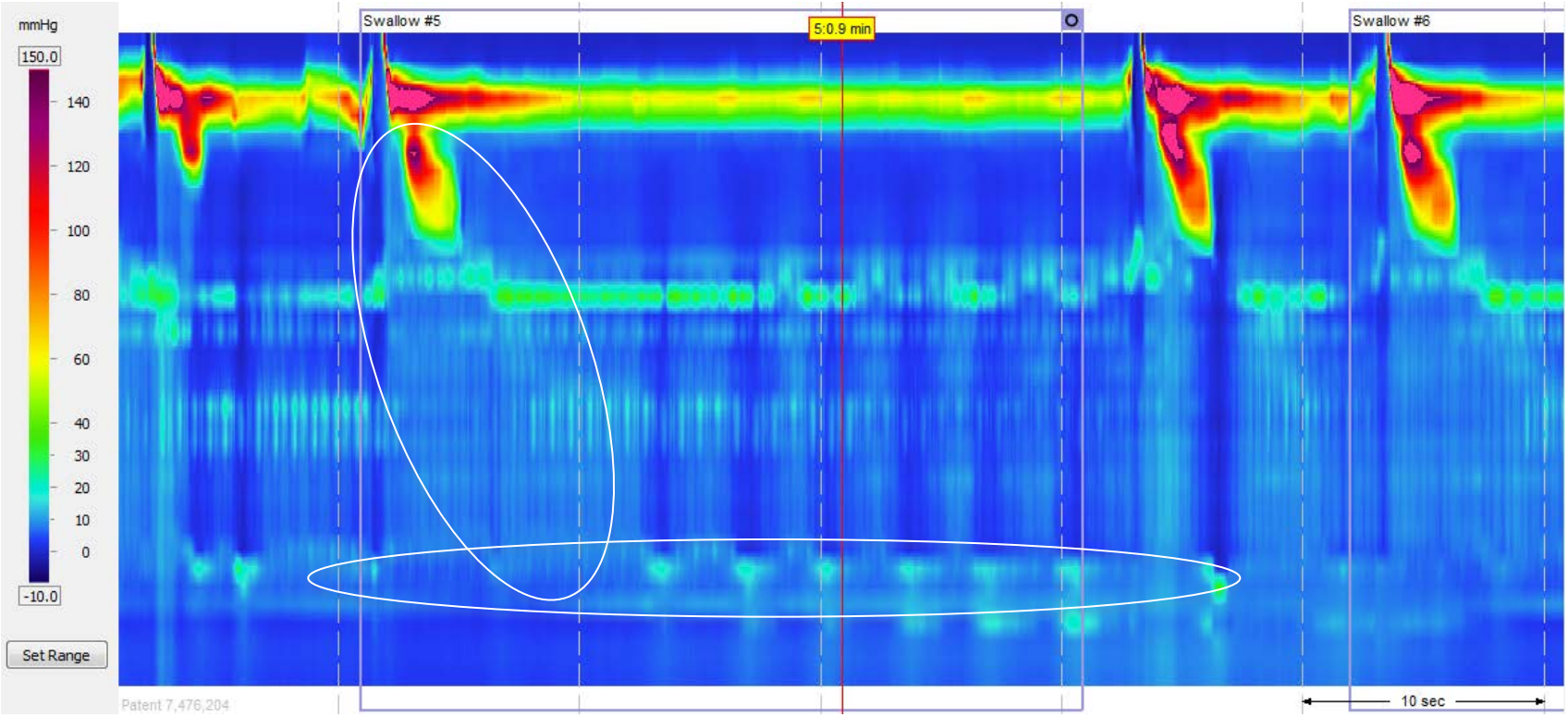
mmHg
150.0
140
120
100
80
60
40
30
20
10
0
-10.0
Set Range
Patent 7,476,204
Swallow #5
5:0.9 min
Swallow #6
10 sec

Case #1

Jeff, a 32 y.o. male pharmacist, referred to you in your outpatient clinic with a complaint of “I feel something stuck when I eat”.

- PMHx: none
- Medications: Ranitidine 150mg PRN
- Physical Exam: BMI 30, Normal chest/cardiovascular exam, Benign abdomen
- Bloodwork: Normal CBC, lytes, Cr

Case #1

Jeff tells you:

- dysphagia is intermittent, started 3-4 years ago, gradually getting m
- difficulty swallowing with solid and liquids
- increasing heartburn lately
  - using Ranitidine almost on a daily basis for the past month

What is your differential diagnosis?

Case #1

On further questioning:

- lost 5 kg over past 3 months due to difficulty swallowing, but no other B symptoms
- family history positive for esophageal cancer in a paternal uncle
- chronic intermittent heartburn x few years, recent onset of regurgitation
- no chest pain
- denies skin thickening/tightening, joint pain, Raynaud's phenomenon
- ex-smoker quitted 5 years ago, social alcohol use
- never had endoscopy

Case #1

What would you do now for Jeff?

What can you do in the meantime while patient awaits for endoscopy?

Trial of PPI BID x 4 weeks

On endoscopy…

What is the diagnosis?

On EMS…

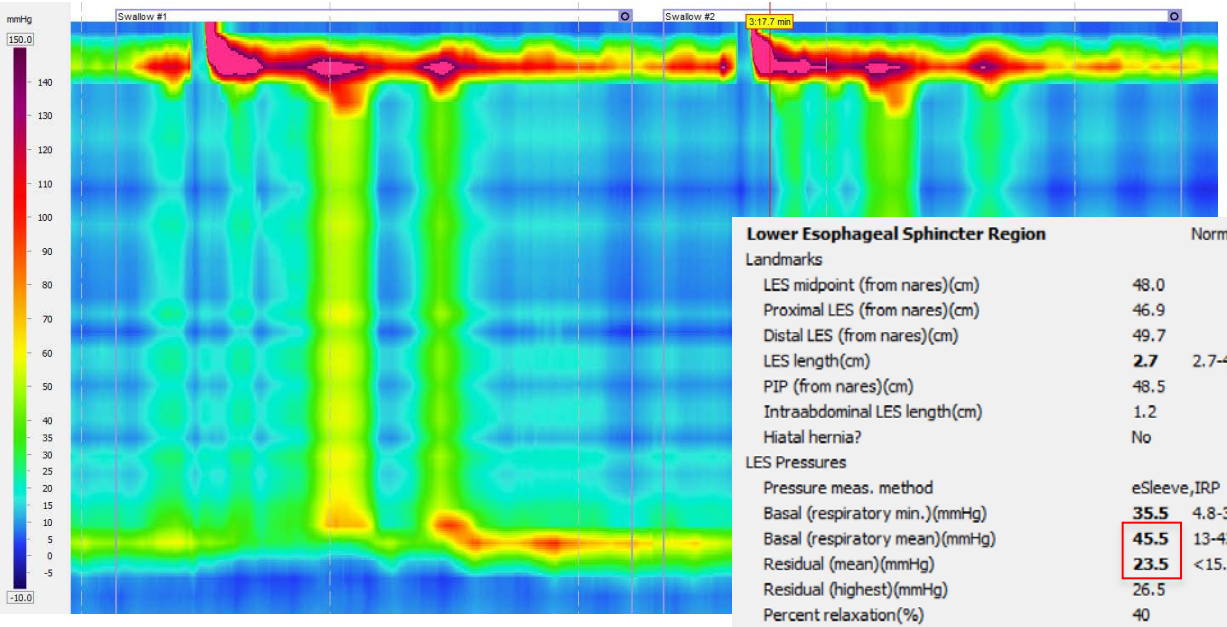

Lower Esophageal Sphincter Region		Normal
Landmarks		
LES midpoint (from nares)(cm)	48.0	
Proximal LES (from nares)(cm)	46.9	
Distal LES (from nares)(cm)	49.7	
LES length(cm)	**2.7**	2.7-4.8
PIP (from nares)(cm)	48.5	
Intraabdominal LES length(cm)	1.2	
Hiatal hernia?	No	
LES Pressures		
Pressure meas. method	eSleeve,IRP	
Basal (respiratory min.)(mmHg)	**35.5**	4.8-32.0
Basal (respiratory mean)(mmHg)	**45.5**	13-43
Residual (mean)(mmHg)	**23.5**	<15.0
Residual (highest)(mmHg)	26.5	
Percent relaxation(%)	40	

Esophageal Motility		Normal
Number of swallows evaluated	10	
Evaluated @ 3.0 - 11.0 above LES		
Peristaltic (velocity ≤ 6.25 cm/s)(%)	0	
Simultaneous (vel. ≥ 6.25 cm/s)(%)	**100**	≤10%
Failed(%)	0	0%
Evaluated @ 3.0 & 7.0 above LES		
Mean wave amplitude(mmHg)	**28.8**	43-152
Double-peaked waves(%)	0	≤15%
Triple-peaked waves(%)	0	0%
Velocity (11.0-3.0 above LES)(cm/s)	**58.6**	2.8-6.3

☑ Include UES/Pharynx Results

Upper Esophageal Sphincter		Normal
Mean basal pressure(mmHg)	56.0	34-104
Mean residual pressure(mmHg)	8.1	<12.0
Relaxation time-to-nadir(ms)	150	74-365

Pharyngeal / UES Motility		Normal
No. swallows evaluated	10	
Evaluated @ 2.0 & N/A above UES		
Mean peak pressure(mmHg)	7.7	
Peak pressure @ N/A above mid UES(mmHg)	N/A	

Treatment

- Jeff proceeded with pneumatic dilatation

Tack and Zaninotto. *Nature Reviews Gastroenterology & Hepatology*, 2015.

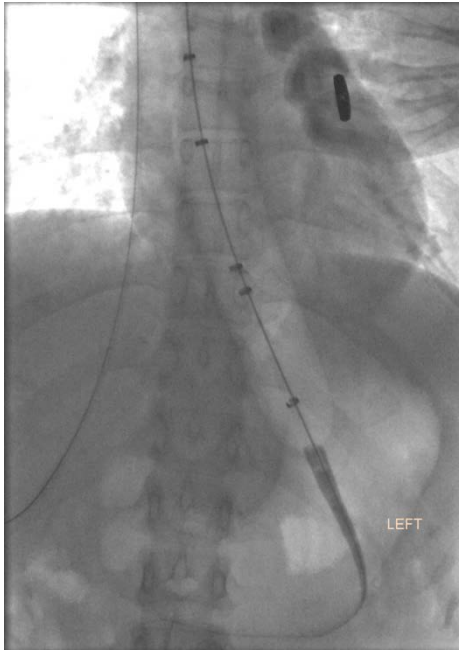

EMS one month later…

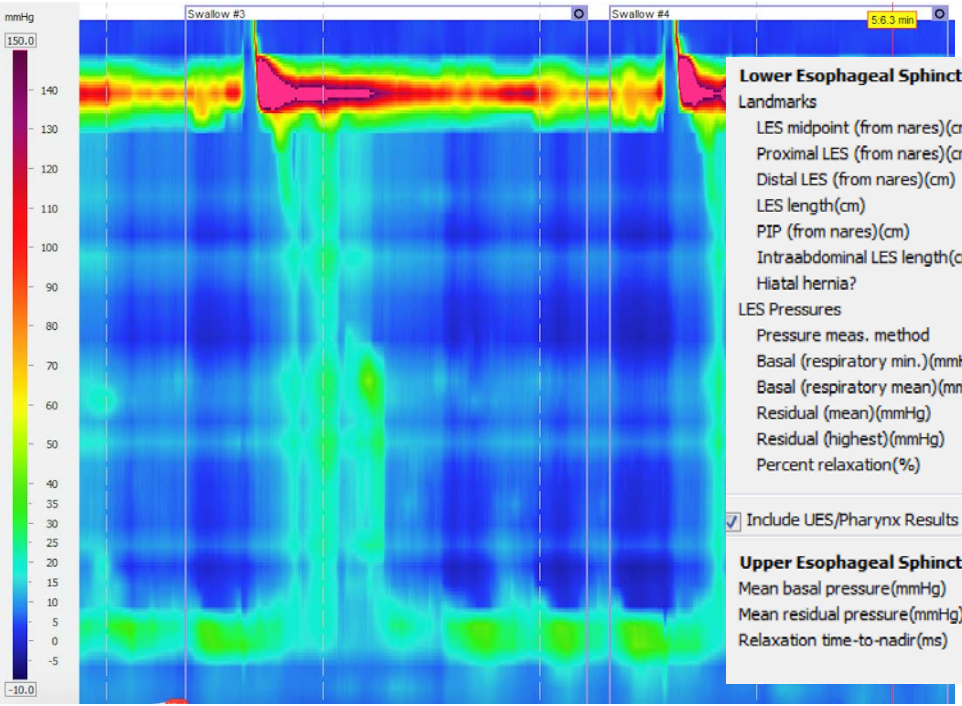

Lower Esophageal Sphincter Region		Normal
Landmarks		
LES midpoint (from nares)(cm)	44.4	
Proximal LES (from nares)(cm)	43.4	
Distal LES (from nares)(cm)	45.1	
LES length(cm)	**1.8**	2.7-4.8
PIP (from nares)(cm)	46.6	
Intraabdominal LES length(cm)	0.0	
Hiatal hernia?	**Yes, 1.5**	
LES Pressures		
Pressure meas. method	eSleeve,IRP	
Basal (respiratory min.)(mmHg)	9.0	4.8-32.0
Basal (respiratory mean)(mmHg)	14.2	13-43
Residual (mean)(mmHg)	11.1	<15.0
Residual (highest)(mmHg)	14.5	
Percent relaxation(%)	36	

Esophageal Motility		Normal
Number of swallows evaluated	10	
Evaluated @ 3.0 - 11.0 above LES		
Peristaltic (velocity ≤ 6.25 cm/s)(%)	0	
Simultaneous (vel. ≥ 6.25 cm/s)(%)	**50**	≤10%
Failed(%)	**50**	0%
Evaluated @ 3.0 & 7.0 above LES		
Mean wave amplitude(mmHg)	**21.9**	43-152
Double-peaked waves(%)	**20**	≤15%
Triple-peaked waves(%)	0	0%
Velocity (11.0-3.0 above LES)(cm/s)	**39.2**	2.8-6.3

☑ Include UES/Pharynx Results

Upper Esophageal Sphincter		Normal
Mean basal pressure(mmHg)	36.2	34-104
Mean residual pressure(mmHg)	0.5	<12.0
Relaxation time-to-nadir(ms)	162	74-365

Pharyngeal / UES Motility		Normal
No. swallows evaluated	10	
Evaluated @ 2.0 & N/A above UES		
Mean peak pressure(mmHg)	4.6	
Peak pressure @ N/A above mid UES(mmHg)	N/A	

Case #2

- 56 yr male, “Sugarbaker” operation for pseudomyxoma pertonei (previous adenoCA appendix 18 yrs ago), postop unable to swallow, even saliva.
- Previously had food obstruction 16 years ago treated with gastroscopy + dilatation, no problems with swallowing since, no heartburn, no problems swallowing prior to surgery.
- Upper GI xray was performed

Achalasia on Barium Swallow

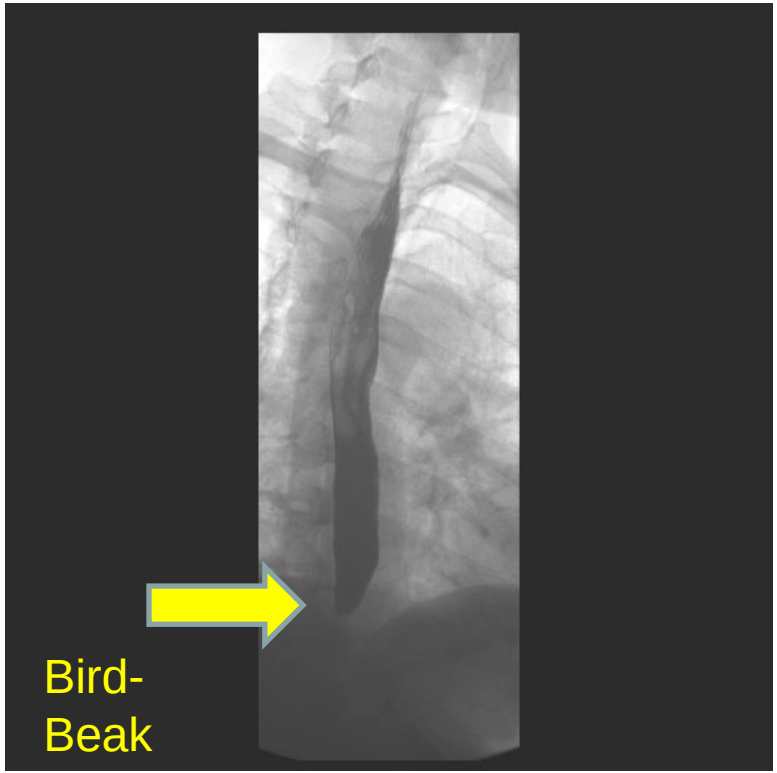

Case #2

- Achalasia appearance reported on the X-ray
- Upper GI endoscopy performed; partial gastrectomy + Billroth II gastrojejunostomy
- No esophageal stricture or esophagitis seen, successful dilatation of esophagus to 17 mm
- Dysphagia returned within a day
- EMS with impedance performed

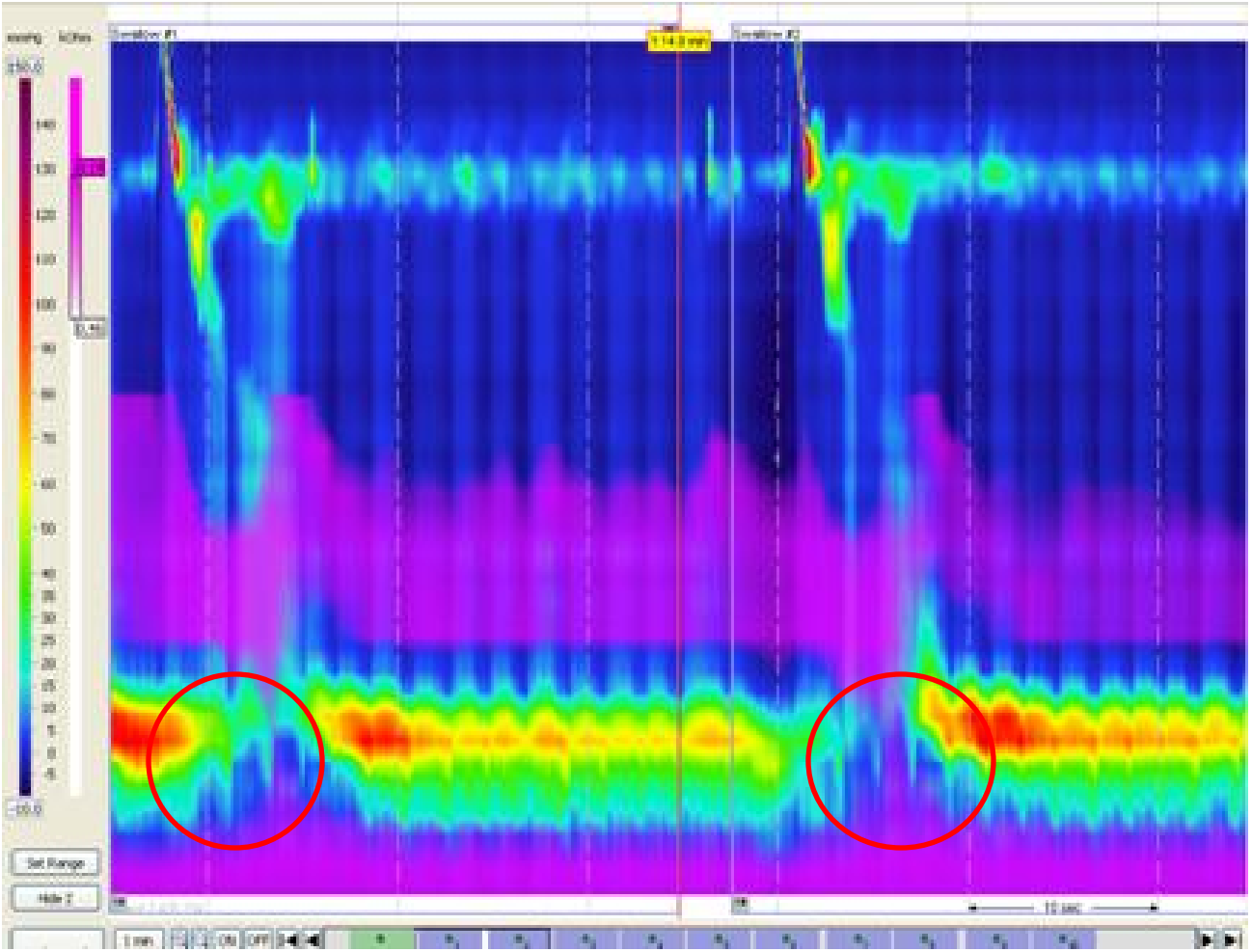
Set Range
Hide Z
1 min
ON
OFF

Motility Report

Report

☑ Include LES/Esoph Motility Summary

Lower Esophageal Sphincter Region		Normal
Landmarks		
LES midpoint (from nares)(cm)	44.8	
Proximal LES (from nares)(cm)	42.8	
Distal LES (from nares)(cm)	47.0	
LES length(cm)	4.1	2.7-4.8
Esophageal length (LES-UES centers)(cm)	23.8	
PIP (from nares)(cm)	45.0	
Intraabdominal LES length(cm)	2.0	
Hiatal hernia?	No	
LES Pressures		
Pressure meas. method	eSleeve,IRP	
Basal (respiratory min.)(mmHg)	**83.7**	18-32.0
Basal (respiratory mean)(mmHg)	**98.8**	13-43
Residual (mean)(mmHg)	**19.2**	<15.0
Residual (highest)(mmHg)	33.5	
Percent relaxation(%)	69	

Esophageal Motility		Normal
Number of swallows evaluated	10	
Evaluated @ 3.0 - 11.0 above LES		
Peristaltic (velocity ≤ 6.25 cm/s)(%)	10	
Simultaneous (vel. ≥ 6.25 cm/s)(%)	**20**	≤10%
Failed(%)	**70**	0%
Evaluated @ 3.0 & 7.0 above LES		
Mean wave amplitude(mmHg)	64.9	43-152
Mean wave duration(s)	3.9	2.7-5.4
Double-peaked waves(%)	**33**	≤15%
Triple-peaked waves(%)	0	0%
Velocity (11.0-3.0 above LES)(cm/s)	**43.9**	2.8-6.3
Velocity (11.0-7.0 above LES)(cm/s)	**39.4**	2.6-8.4
Velocity (7.0-3.0 above LES)(cm/s)	**24.1**	1.8-6.8
Wave ampl. @ 11.0 above LES(mmHg)	62.9	36-134
Wave ampl. @ 7.0 above LES(mmHg)	50.6	37-166
Wave ampl. @ 3.0 above LES(mmHg)	79.2	41-168
Wave duration @ 11.0 above LES(s)	3.2	2.8-4.1
Wave duration @ 7.0 above LES(s)	3.5	2.7-5.2
Wave duration @ 3.0 above LES(s)	4.3	2.4-5.6
High Resolution Parameters		
Distal contractile integral(mean)(mmHg-cm-s)	1342.3	500-5000
Distal contractile integral(highest)(mmHg-cm-s)	2877.4	
Contractile front velocity(cm/s)	**47.0**	<9.0
Intrabolus pressure (@LESR)(mmHg)	6.2	<8.4
Intrabolus pressure (avg max)(mmHg)	13.6	<17.0

☑ Include UES/Pharynx Results

Upper Esophageal Sphincter		Normal
Location (center, fr. nares)(cm)	21.0	
Mean basal pressure(mmHg)	**12.1**	34-104
Mean residual pressure(mmHg)	8.4	<13.0

Pharyngeal / UES Motility		Normal
No. swallows evaluated	10	
Evaluated @ 2.0 & N/A above UES		
Mean peak pressure(mmHg)	8.5	

What approach would you take now?

Recap of the story

- 56 yr male, minimal problems swallowing until he had a major abdominal surgical procedure (Sugarbaker operation)
- Barium swallow shows changes suspicious for Achalasia
- No stricture or esophagitis (or NG tube trauma) seen at gastroscopy
- EMS shows no emptying of esophagus (with Impedance catheter) and high pressure LES
- CT scan shows no evidence of any mass or tumour in the mediastinum, the stomach was well visualized and no tumour, no lesion in the cardia of the stomach.
- A therapeutic procedure was done

Treatment

- Repeat gastroscopy and Botox 100 units injected into the LES
- Patient report marked improvement in swallowing almost immediately
- Continues to have no problems with swallowing
- Repeat EMS done 6 months later…

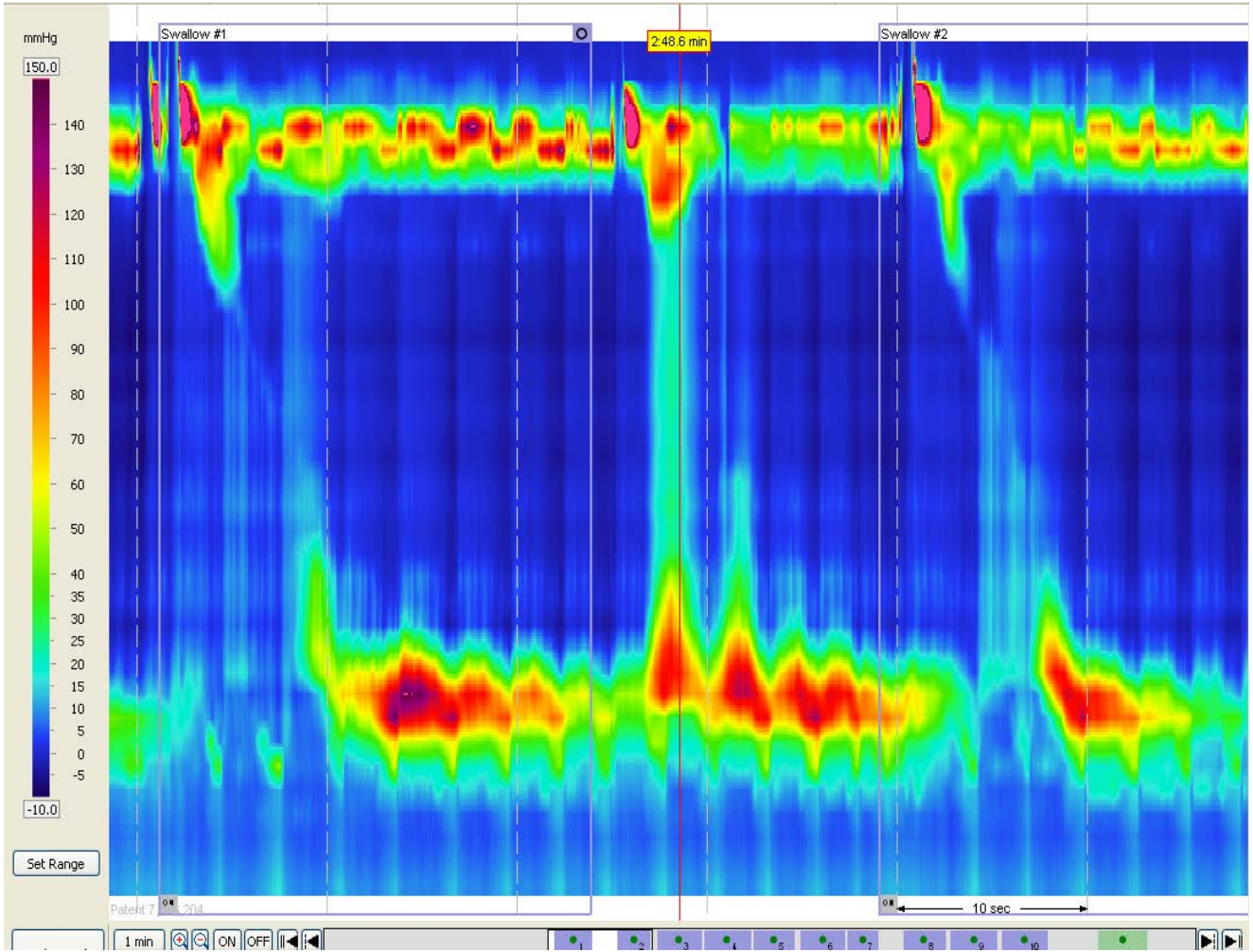
mmHg
150.0
140
130
120
110
100
90
80
70
60
50
40
35
30
25
20
15
10
5
0
-5
-10.0
Set Range
Swallow #1
2:48.6 min
Swallow #2
10 sec
1 min
ON
OFF

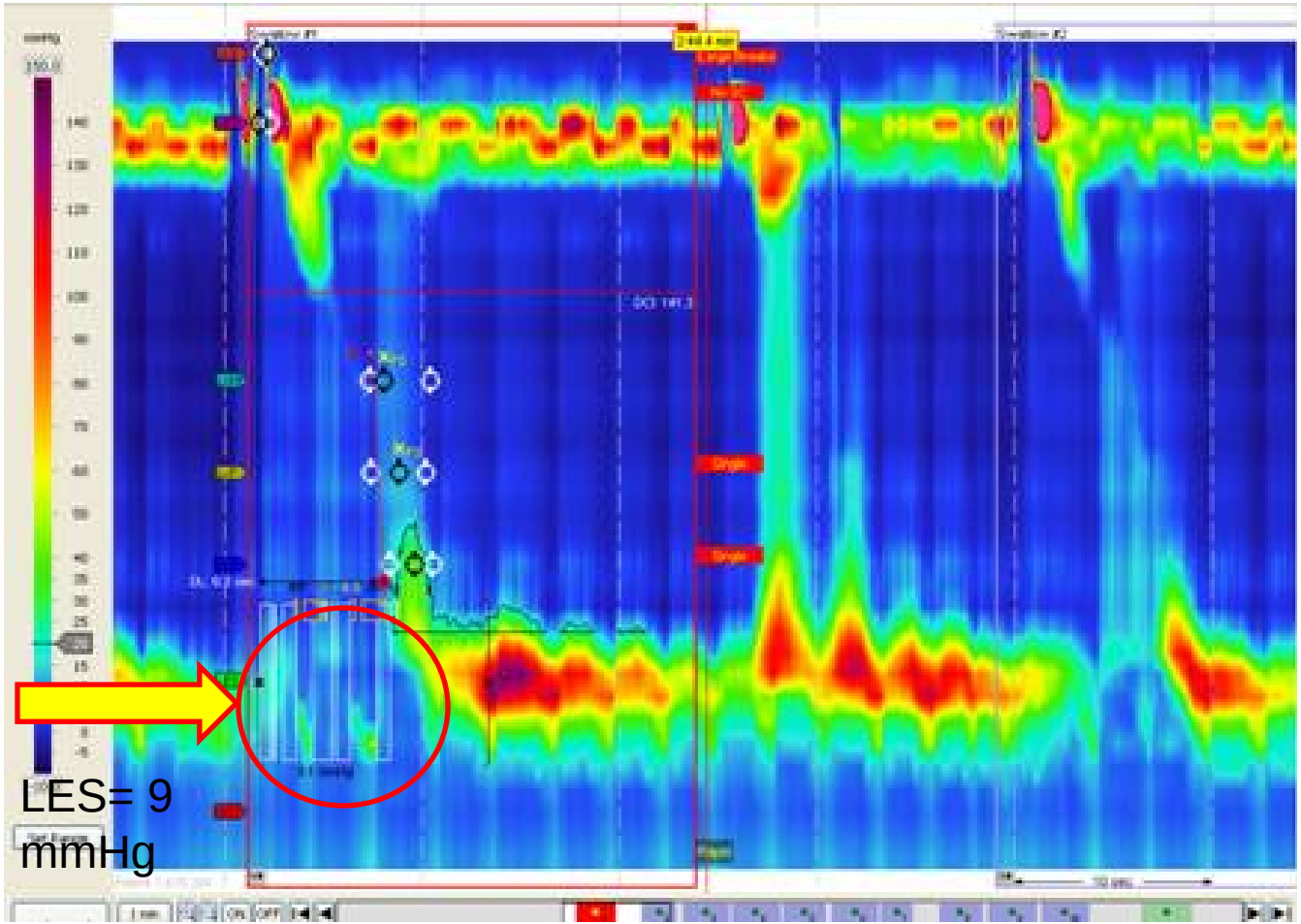
LES= 9
mmHg

Evaluation and Certificate of Attendance

Please download the CDDW™ app to complete the session evaluation and to receive your certificate of attendance.